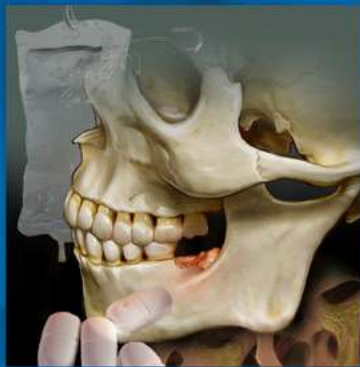

# ENDODONTICS

*Colleagues for  
Excellence*



Fall 2012

*Bisphosphonate-Associated  
Osteonecrosis of the Jaw*



Published for the Dental Professional Community by the  
**American Association of Endodontists**

[www.aae.org/colleagues](http://www.aae.org/colleagues)

There has been a burgeoning demand for information about bisphosphonates over the past 10 years due to an increasing awareness of this drug's rare adverse side effect of osteonecrosis of the jaw. The medical and dental communities' realization of this complication has been correspondingly disseminated to the public through various media outlets, websites and position statements proffered by the United States Food and Drug Administration, as well as several pharmaceutical companies. One only has to venture through the multitude of Internet search engines to see that the legal community is also an interested party to bisphosphonate-associated osteonecrosis of the jaw.

The dental profession is in an advantageous position to educate the public and fellow health care professionals, as well as be at the forefront in diagnosing this condition. It is incumbent upon dental health care providers to be knowledgeable about this issue and acquainted with the most current treatment recommendations and guidelines available. The goal of this informational article is to enhance your understanding about this frequently prescribed class of drugs with regards to its pharmacokinetics, mode of action, types of bisphosphonates and the implications of BONJ.

The first case reports describing a possible relationship between bisphosphonate therapy and osteonecrosis of the jaw published in the *Journal of Endodontics* and the *Journal of the American Dental Association* termed the phenomenon as bisphosphonate-associated osteonecrosis of the jaw or BONJ. Other dental specialty communities and authors have referred to the condition by various other names including bisphosphonate-related osteonecrosis of the jaw and bisphosphonate-induced osteonecrosis of the jaw. With the advent of antiresorptive agents other than bisphosphonates being associated with ONJ, the nomenclature of the condition has continued to evolve. In recognition of these other antiresorptive agents, the ADA Council on Scientific Affairs, in its November 2011 Recommendations for Managing the Care of Patients Receiving Antiresorptive Therapy for Prevention and Treatment of Osteoporosis, proposed that all cases of ONJ related to the administration of antiresorptive therapeutic agents be termed antiresorptive agent-induced osteonecrosis of the jaw. To avoid confusion and for purposes of continuity, the AAE Specialty Committee on Bisphosphonates recommends the continued use of the term bisphosphonate-associated osteonecrosis of the jaw with the understanding that that term is meant to be inclusive of these other antiresorptive agents.

### **Use of Bisphosphonates**

In 2006, total U.S. prescriptions for oral bisphosphonates exceeded 30 million.<sup>1</sup> America's aging baby boomer population will likely produce an amplification of those numbers over the next two decades. Bone fractures are the biggest problem facing most older individuals with bone disease, especially those with osteoporosis. The cumulative impact of these fractures can be devastating. Osteoporotic fractures in the United States in 1995 led to more than half a million hospitalizations, over 800,000 emergency room encounters, more than 2.6 million physician office visits and the placement of nearly 180,000 individuals into nursing homes (U.S. Surgeon General Report 2004). It has been estimated that, over a 10-year period, white women age 45 and older in the United States could experience 5.2 million fractures of the hip, spine or forearm, resulting in two million person-years of disability related to the fractures. Bisphosphonates are generally prescribed in the prevention and treatment of resorptive bone diseases such as osteoporosis and bone metastasis (with or without hypercalcemia) associated with breast and prostate cancers. They are also recognized as an effective therapeutic for Paget's disease (*osteodystrophy deformans*) and other conditions that precipitate bone fragility, such as chronic renal disease in patients undergoing dialysis.<sup>2</sup>

### **Bisphosphonates and Osteonecrosis of the Jaw**

Bonefos® (clodronate) and Didronel® (etidronate), both first-generation bisphosphonates do not have an amino group moiety (nitrogen-containing) on the R2 long side-chain. It is the R2 side-chain that imparts the potency and method of affect on bone cells. Therefore, first-generation bisphosphonates (non-nitrogen containing) do not appear to be implicated in BONJ. Second- and third-generation bisphosphonates (nitrogen-containing), including Zometa® (zoledronate), Reclast® (zoledronate), Aredia® (pamidronate), Boniva® (ibandronate), Actonel® (risedronate) and Fosamax® (alendronate), inhibit specific enzymatic activity necessary for osteoclast bone resorption.<sup>3-7</sup> Bisphosphonates are administered either parenterally (intravenously) or orally. What is significant to these two routes of administration is the bioavailability of the drug. The oral bioavailability is in the area of one percent due to the higher ionization at physiologic pH when absorbed through the intestinal mucosa.<sup>8</sup> Greater bioavailability through parenteral administration and concomitant potency are likely responsible for the higher incidence of BONJ in this group.

The accumulated body of literature is replete with case reports, letters to the editor, reviews and drug alerts by the

U.S. FDA and pharmaceutical companies.<sup>9-27</sup> This collective information points to an association between bisphosphonates and ONJ. With limited current available randomized controlled trials or higher levels of clinical evidence, the following information is presented based mostly on retrospective analysis of case reports and expert opinions.

### **Other Antiresorptive Agents and Osteonecrosis of the Jaw**

Nonbisphosphonate antiresorptive agents have recently become available. One such agent is Prolia® (denosumab), which received FDA approval in 1997 for the treatment of osteoporosis in postmenopausal women.<sup>28</sup> Denosumab is a monoclonal antibody that acts in a similar fashion to bisphosphonates, reducing bone resorption by inhibiting osteoclast function.<sup>29</sup> There is at least one case report of ONJ developing in a cancer patient taking denosumab.<sup>30</sup> Other antiresorptive agents that could prove to be associated with ONJ include cathepsin K-inhibitors, anabolic agents and angiogenesis inhibitors.<sup>28</sup> One such cathepsin K-inhibitor is odanacatib, which increased bone mineral density in postmenopausal women after two years with side effects similar to a placebo.<sup>31</sup>

### **Signs and Symptoms of BONJ**

- An irregular mucosal ulceration with exposed bone in the mandible or maxilla persisting for longer than eight weeks
- Pain or swelling in the affected jaw without evidence of dental pathology
- Infection with or without purulence
- An altered sensation (*e.g.*, numbness or heavy sensation)

Additional important issues related to BONJ include:

- The site of occurrence of osteonecrosis is the jaws; presentation occurs more frequently in the mandible than the maxilla.
- The exact mechanism for bisphosphonate-associated ONJ is unknown. However, evidence suggests bisphosphonates inhibit osteoclastic function, induce apoptosis of osteoclasts and inhibit osteoclast differentiation from precursors.<sup>32</sup> They may also inhibit angiogenesis but this effect is less clear and may be variable.<sup>33-35</sup>
- Screening tests used for the purpose of determining a patient's risk of developing BONJ, such as C-terminal cross-linking telopeptide of Type I collagen (CTX) and urinary N-telopeptide of Type I collagen (NTX) levels, do not display sufficient evidence to recommend their use.<sup>36</sup>
- The treatment for BONJ is problematic. Case reports document no response or a limited response to local surgical wound debridement, marginal or segmental resection, antibiotics and hyperbaric oxygen. Therefore, recognition of risk factors and application of preventive dental treatment procedures are important for patients taking I.V. and perhaps oral bisphosphonates.

Common risk factors associated with BONJ:

- History of taking bisphosphonates, especially I.V. formulations.
- At this time, the concurrent use of steroids has not consistently been found to be a risk factor.<sup>19, 37-38</sup> Literature to the contrary is largely based on expert opinion and hypothesis.<sup>39</sup>
- Previous history of cancer (*e.g.*, multiple myeloma or metastatic disease to bone), osteoporosis, Paget's disease, chronic renal disease on dialysis or other indications for bisphosphonate treatment.
- A history of a traumatic dental procedure. Most case reports occur after a tooth extraction, although other traumatic dental procedures may also be associated with the occurrence of ONJ. One case report describes BONJ occurring six months after placement of five dental implants with the subsequent loss of all implants.<sup>40</sup>
- Several reports indicate the spontaneous development of BONJ without a prior traumatic dental procedure.

It is now well-established that BONJ is a class effect of the subclass termed nitrogen-containing bisphosphonates (*i.e.*, may occur with all nitrogen-containing bisphosphonates with the incidence varying according to potency or other factors) rather than a drug effect (*i.e.*, observed with only a few nitrogen-containing bisphosphonates). To date, the majority of reports have described ONJ occurring in patients undergoing bisphosphonate infusion (*e.g.*, Zometa® [zoledronate], Reclast®

[zoledronate] and Aredia® [pamidronate]). Nevertheless, in several publications, oral bisphosphonates have been associated with ONJ.<sup>19,22-23,41-42</sup> A FDA Office of Drug Safety Post-Marketing Safety Review stated that BONJ “may be a class effect.”<sup>42</sup> Revised product packages for oral bisphosphonate medications (e.g., Fosamax® [alendronate] and Actonel® [risedronate] list BONJ as a possible adverse side effect.<sup>43-44</sup>

### **Incidence of BONJ**

Currently, there are few studies that adequately address the incidence of BONJ. However, recent literature suggests that patients receiving bisphosphonates intravenously for cancer therapy for extended periods (e.g., >2 years with zoledronate) have a risk of developing BONJ of between 0.8% and 20%, and patients receiving oral bisphosphonate therapy have a risk of developing BONJ of between 0 and 0.04%.<sup>45-51</sup> In one survey of respondents taking oral bisphosphonates, the risk of developing BONJ was approximately 0.1%.<sup>40</sup> However, safety data acquired recently from two controlled studies in patients receiving an oral bisphosphonate, Fosamax® (alendronate), showed no correlation between oral bisphosphonates and BONJ. Study 1 tested the effect of alendronate on alveolar bone in 335 patients in a randomized clinical trial using a placebo or 70 mg of alendronate weekly for two years. Study 2, a longitudinal, single-blind, controlled design compared success in 50 consecutive patients. The study covered implant success and safety, also determining occurrence of BONJ. No incidence of BONJ was observed in either study. The conclusion of these two studies was that oral bisphosphonate usage was not associated with occurrence. However, the maximum length of follow-up in these studies was only three years and the sample sizes may not have been large enough to identify the small incidence of BONJ.<sup>52</sup> To date, there are no case reports that directly or indirectly implicate endodontic treatment in the development of BONJ. One case report suggested an association, but the assertion was not supported by the evidence presented in the report.<sup>53</sup>

Pending the availability of more definitive information, prudence should govern all patient treatment considerations for individuals on bisphosphonates. The magnitude of risk for BONJ likely varies with the bisphosphonate taken, duration of usage, patient factors (e.g., concurrent drugs, diseases, etc.) and dental treatment.<sup>39,54</sup> The existing knowledge at this time strongly suggests that patients on I.V. bisphosphonates have a higher risk for developing BONJ, while patients taking oral bisphosphonates have a significantly lower risk. However, even if there were numerous published studies that adequately addressed the incidence of BONJ, it would still be impossible to predict a specific patient’s risk.<sup>28</sup>

### **Commonly Prescribed Bisphosphonates**

Subclass of Bisphosphonate	Generic Name	Trade Name	Route of Administration	Potency Ratings
Aminobisphosphonate	Zoledronate	Zometa®, Reclast®	I.V.	10,000
Aminobisphosphonate	Pamidronate	Aredia®	Oral & I.V.	100
Aminobisphosphonate	Alendronate	Fosamax®	Oral	500
Aminobisphosphonate	Ibandronate	Boniva®	Oral & I.V.	1,000
Aminobisphosphonate	Risedronate	Actonel®	Oral	2,000
Nonaminobisphosphonate	Tiludronate	Skelid®	Oral	10
Nonaminobisphosphonate	Clodronate	Bonefos®, Loron®, Ostac®	Oral	10
Nonaminobisphosphonate	Etidronate	Didronel®	Oral	1 (potency relative to that of etidronate)

### **Recommendations and Guidelines**

The following is recommended when considering the endodontic implications in treating patients taking bisphosphonates:

#### ***I.V. Bisphosphonate Guidelines:***

- Patients taking I.V. bisphosphonates are at higher risk for developing BONJ. Preventive procedures are very important to reduce the risk of developing BONJ because treatment of BONJ is not predictable at this time. Preventive care might include caries



control, conservative periodontal and restorative treatments, and, if necessary, appropriate endodontic treatment. Similar to the management of the patient with osteoradionecrosis, this might include nonsurgical endodontic treatment of teeth that otherwise would be extracted. Nonrestorable teeth may be treated by removal of the crown, endodontic treatment of remaining roots and restoration similar to preparing an overdenture abutment.

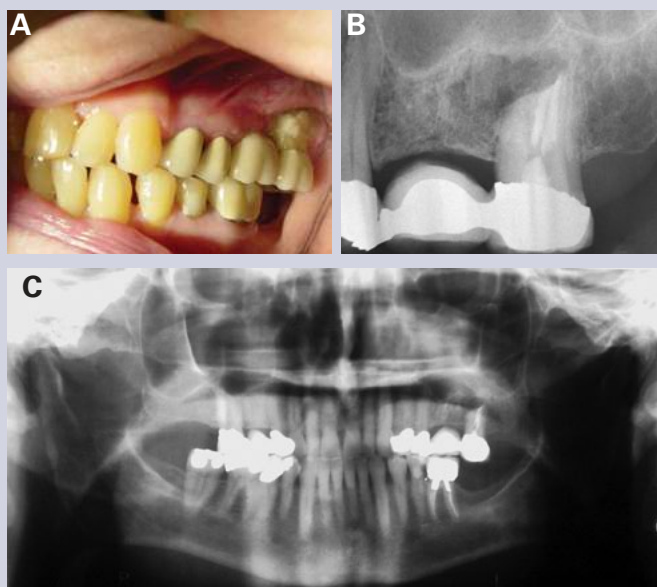
- Surgical procedures such as tooth extractions, endodontic surgical procedures or placement of dental implants appear to pose an increased risk for developing osteonecrosis of the jaws and should be avoided if possible.

**Oral Bisphosphonate Guidelines:**

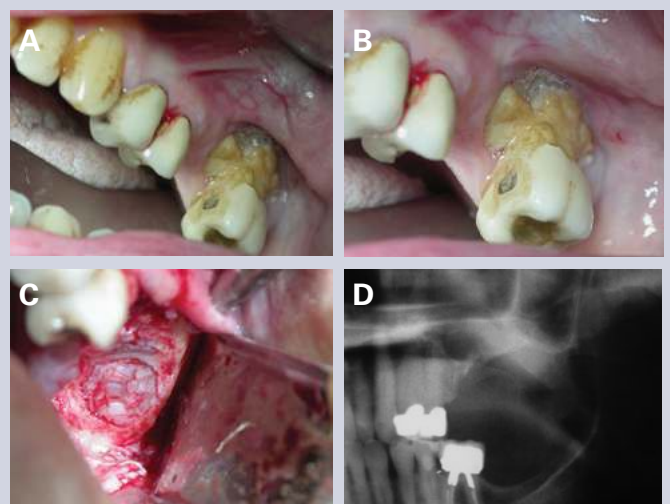
- Patients taking oral bisphosphonates are at lower risk for developing BONJ. Appropriate clinical procedures might include intraoral examination, indicated dental procedures (e.g., regular checkups, caries control, indicated periodontal and restorative treatments), and patient education about the symptoms of bisphosphonate-associated osteonecrosis of the jaws and their relatively low risk of developing ONJ from surgery or soft tissue procedures.

**General Guidelines and Recommendations:**

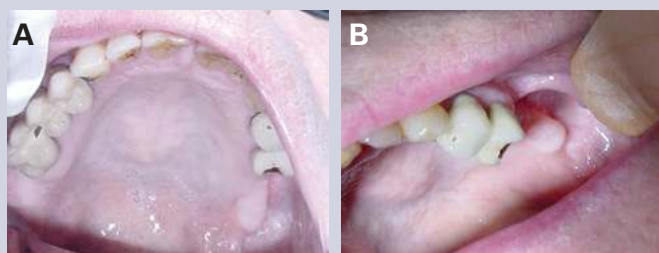
- Recognize the risk factors of BONJ.
- As usual, informed consent for endodontic procedures should involve a discussion of risks, benefits and alternative treatments with the patient.
- Consider BONJ when developing a differential diagnosis of nonodontogenic pain.
- Utilize the entire health care team, including the patient's general dentist, oncologist and oral surgeon, when developing treatment plans for these patients.
- Cases of BONJ should be reported to the U.S. FDA MedWatch Online at [www.accessdata.fda.gov/scripts/medwatch](http://www.accessdata.fda.gov/scripts/medwatch).
- Additional background information on how to report adverse effects of drugs can be found at [www.fda.gov/opacom/backgrounders/problem.html](http://www.fda.gov/opacom/backgrounders/problem.html).
- Be aware that the knowledgebase for BONJ is rapidly increasing and it is likely that these recommendations may change over time. The prudent practitioner is encouraged to continually review publications for new developments and treatments in antiresorptive therapy.



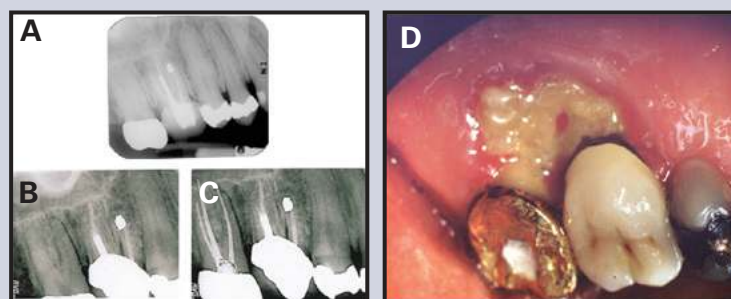
**Figure 1.** (A) Clinical presentation of posterior left quadrant and exposed bone #15. (B) Periapical radiograph of tooth #15 at presentation. (C) Panoramic radiograph at presentation. Sarathy et al. **Bisphosphonate-Associated Osteonecrosis of the Jaws and Endodontic Treatment: Two Case Reports.** *Journal of Endodontics* 2005;10:759-63. ©Copyright 2005. Reproduced with permission.



**Figure 2.** (A) View of upper left quadrant after sectioning of pontic. (B) Close-up view of tooth #15 and bone exposure. (C) Intraoperative view demonstrating intact sinus membrane. (D) Immediate postoperative close-up of panoramic film of operative site showing intact sinus wall. Sarathy et al. **Bisphosphonate-Associated Osteonecrosis of the Jaws and Endodontic Treatment: Two Case Reports.** *Journal of Endodontics* 2005;10:759-63. ©Copyright 2005. Reproduced with permission.



**Figure 3.** (A) A six-month postoperative occlusal view of surgical site. (B) A six-month postoperative facial view of surgical site. Sarathy et al. **Bisphosphonate-Associated Osteonecrosis of the Jaws and Endodontic Treatment: Two Case Reports.** *Journal of Endodontics* 2005;10:759-63. ©Copyright 2005. Reproduced with permission.



**Figure 4.** (A) Radiograph before periodontal surgery. (B, C) Preoperative and post-endodontic radiographs. (D) Clinical photograph of case #2. Katz H. **Endodontic Implications of Bisphosphonate-Associated Osteonecrosis of the Jaws: A Report of Three Cases.** *Journal of Endodontics* 2005;11:831-34. ©Copyright 2005. Reproduced with permission.

## References

1. Drug Topics. Top 200 brand-name drugs by unit in 2006. Accessed Sep 5, 2007 at [www.drugtopics.com/drugtopics/Pharmacy+Facts+Figures/Top-200-brand-name-drugs-in-2006/ArticleStandard/Article/detail/407649?contextCategoryID=7604](http://www.drugtopics.com/drugtopics/Pharmacy+Facts+Figures/Top-200-brand-name-drugs-in-2006/ArticleStandard/Article/detail/407649?contextCategoryID=7604)
2. Bisphosphonate. Accessed Sep 3, 2012 at <http://en.wikipedia.org/wiki/bisphosphonate>.
3. Reszka AA, Rodan GA. Mechanism of action of bisphosphonates (review). *Curr Osteoporos* 2003;1:45-52.
4. Reszka AA, Rodan GA. Nitrogen-containing bisphosphonate mechanism of action (review). *Mini Rev Med Chem* 2004;4:711-9.
5. Rogers MJ. New insights into the molecular mechanisms of action of bisphosphonates (review). *Curr Pharm Des* 2003;9:2643-58.
6. Stavropoulos MF, Fitzpatrick S, Bowers AN, Neuman AN, et al. Development of bisphosphonate-related osteonecrosis of the jaws in patients treated with annual zoledronic acid infusion (Reclast®) with history of oral bisphosphonate use: a case series. *Int J Oral Maxillofac Surg* 2011;40:1167.
7. van Beek ER, Cohen LH, Leroy IM, Ebetino FH, et al. Differentiating the mechanisms of antiresorptive action of nitrogen containing bisphosphonates. *Bone* 2003;33:805-11.
8. Ezra A, Golub G. Administration routes and delivery systems of bisphosphonates for the treatment of bone resorption. *Adv Drug Deliv Rev* 2000;42:175-95.
9. Carter GD, Goss AN. Bisphosphonates and avascular necrosis of the jaws. *Aust Dent J* 2003;48:268.
10. Carter G, Goss AN, Doecke C. Bisphosphonates and avascular necrosis of the jaw: a possible association. *Med J Aust* 2005;182:413-5.
11. Cheng A, Mavrokokki A, Carter G, Stein B, Fazzalari N, Wislon D, Goss AN. The dental implications of bisphosphonates and bone disease. *Aust Dent J* 2005;50(4 Suppl 2):S4-13.
12. Cheung WK, et al. Pharmacokinetics of pamidronate disodium in cancer patients single intravenous infusion of 30-, 60- or 90-mg dose over 4 or 24 hours. *Am J Ther* 1994;1:228-35.
13. Durie BG, Katz M, Crowley J. Osteonecrosis of the jaw and bisphosphonates. *N Engl J Med* 2005;353:99-102.
14. Hellstein JW, Marek CL. Bisphosphonate-associated complications of the jaws. *J Oral Maxillofac Surg* 2004;62:1563-5.
15. Katz H. Endodontic implications of bisphosphonate-associated osteonecrosis of the jaws: a report of three cases. *J Endod* 2005;31:831-4.
16. Leite AF, Figueiredo PT, Melo NS, Acevedo AC, Cavalcanti MGP, Paula LM, Guerra ENS. Bisphosphonate-associated osteonecrosis of the jaws. Report of a case and literature review. *Oral Surg, Oral Med, Oral Pathol, Oral Radiol, Endod* 2006;102:14-21.
17. Markiewicz, MR, Margarone JE 3rd, Campbell JH, Aguirre A. Bisphosphonate-associated osteonecrosis of the jaws: a review of current knowledge. *J Am Dent Assoc* 2005;136:1669-74.
18. Marx RE. Pamidronate (Aredia®) and zoledronate (Zometa®) induced avascular necrosis of the jaws: a growing epidemic. *J Oral Maxillofac Surg* 2003;61:1115-7.

19. Marx RE, Sawatari Y, Fortin M, Broumand V. Bisphosphonate-induced exposed bone (osteonecrosis/osteopetrosis) of the jaws: risk factors, recognition, prevention, and treatment. *J Oral Maxillofac Surg* 2005;63:1567-75.
20. Melo MD, Obeid G. Osteonecrosis of the maxilla in a patient with a history of bisphosphonate therapy. *J Can Dent Assoc* 2005;71:111-3.
21. Migliorati CA. Bisphosphonate-associated oral osteonecrosis. *Oral Surg Oral Med Oral Pathol Oral Radiol Endod* 2005;99:135.
22. Migliorati CA, Casiglia J, Epstein J, Jacobsen PL, Siegel MA, Woo SB. Managing the care of patients with bisphosphonate-associated osteonecrosis: an American Academy of Oral Medicine position paper. *J Am Dent Assoc* 2005;136:1658-68.
23. Migliorati CA, Schubert MM, Peterson DE, Seneda LM. Bisphosphonate-associated osteonecrosis of mandibular and maxillary bone: an emerging oral complication of supportive cancer therapy. *Cancer* 2005;104:83-93.
24. Novartis Pharmaceuticals Corporation 2005. Appendix 11: Expert panel recommendations for the prevention, diagnosis and treatment of osteonecrosis of the jaw. Accessed Feb 5, 2012 at [www.fda.gov/ohrms/dockets/ac/05/briefing/2005-4095B2\\_02\\_12-Novartis-Zometa-App-11.pdf](http://www.fda.gov/ohrms/dockets/ac/05/briefing/2005-4095B2_02_12-Novartis-Zometa-App-11.pdf).
25. Sarathy AP, Bourgeois SL Jr, Goodell GG. Bisphosphonate-associated osteonecrosis of the jaws and endodontic treatment: two case reports. *J Endod* 2005;31:759-63.
26. Wooltorton E. Patients receiving intravenous bisphosphonates should avoid invasive dental procedures. *Can Med Assoc J* 2005;172:1684.
27. Zarychanski R, Elphee E, Walton P, Johnston J. Osteonecrosis of the jaw associated with pamidronate therapy. *Am J Hematol* 2006;81:73-5.
28. Managing the care of patients receiving antiresorptive therapy for prevention and treatment of osteoporosis. Executive summary of recommendations from the American Dental Association Council on Scientific Affairs. *J Am Dent Assoc* 2011;142:1243-51.
29. Bekker P, Holloway D, Rasmussen A, et al. A single-dose placebo-controlled study of AMG 162, a fully human monoclonal antibody to RANKL, in postmenopausal women. *J Bone Miner Res* 2004;19:1059-66.
30. Aghaloo TL, Felsenfeld AL, Tetradis S. Osteonecrosis of the jaw in a patient on denosumab. *J Oral Maxillofac Surg* 2010;68:959-63.
31. Bone HG, McClung MR, Roux C, et al. Odanacatib, a cathepsin-K inhibitor for osteoporosis: a two year study in postmenopausal women with low bone density. *J Bone Miner Res* 2010;25:937-47.
32. Lindsay R, Cosman F. Osteoporosis. In: Braunwald E, Fauci AS, Kasper DL, Hauser SL, Longo DL, Jameson JL, eds. *Harrison's principles of internal medicine*. New York:McGraw-Hill, 2001:2226-37.
33. Santini D, Vincenzi B, Dicuonzo G, Avvisati G, Massacesi C, Battistoni F, Gavasci M, Rocci L, Tirindelli MC, Altomare V, Tocchini M, Bonsignori M, Tonini G. Zoledronic acid induces significant and long-lasting modifications of circulating angiogenic factors in cancer patients. *Clin Cancer Res* 2003;9:2893-7.
34. Vincenzi B, Santini D, Dicuonzo G, Battistoni F, Gavasci M, La Cesa A, Grilli C, Virzi V, Gasparro S, Rocci L, Tonini G. Zoledronic acid-related angiogenesis modifications and survival in advanced breast cancer patients. *J Interferon Cytokine Res* 2005;25:144-51.
35. Wood J, Bonjean K, Ruetz S, Bellahcene A, Devy L, Foidart JM, Castronovo V, Green JR. Novel antiangiogenic effects of the bisphosphonate compound zoledronic acid. *J Pharmacol Exp Ther* 2002;302:1055-61.
36. Updated recommendations for managing the care of patients receiving oral bisphosphonate therapy. *J Am Dent Assoc* 2008;139:1674-7.
37. Odvina CV, Zerwekh JE, Rao DS, Maalouf N, Gottschalk FA, Pak CY. Severely suppressed bone turnover: a potential complication of alendronate therapy. *J Clin Endocrinol Metabolism* 2005;90:1294-1301.
38. Barasch A, Cunha-Cruz J, Curro FA, et al. Risk factors for osteonecrosis of the jaws: a case-control study from the CONDOR Dental PBRN. *J Dent Res* 2011;90:439-4.
39. American Association of Oral and Maxillofacial Surgeons position paper on bisphosphonate-related osteonecrosis of the jaw – 2009 update. Accessed on Sep 3, 2012 at [www.aaoms.org/docs/position\\_papers/bronj\\_update.pdf](http://www.aaoms.org/docs/position_papers/bronj_update.pdf).
40. Starck WJ, Epker BN. Failure of osseointegrated dental implants after diphosphonate therapy for osteoporosis: a case report. *Int J Oral Maxillofac Implants* 1995;10:74-8.
41. Chang JS. ODS postmarketing safety review. Department of Health and Human Services, Public Health Service, Food and Drug Administration 2004. [www.fda.gov/ohrms/dockets/ac/05/briefing/2005-4095B2\\_03\\_04-FDA-TAB3.pdf](http://www.fda.gov/ohrms/dockets/ac/05/briefing/2005-4095B2_03_04-FDA-TAB3.pdf).
42. Lo JC, O'Ryan FS, Gordon NP, et al. Prevalence of osteonecrosis of the jaw with oral bisphosphonate exposure. *J Oral Maxillofac Surg* 2010;68:243-53.
43. Merck 2011. Product description of Fosamax®. Accessed Feb 5, 2012 at [www.merck.com/product/usa/pi\\_circulars/f/fosamax/fosamax\\_pi.pdf](http://www.merck.com/product/usa/pi_circulars/f/fosamax/fosamax_pi.pdf).
44. Warner Chilcott 2011. Actonel® prescribing information. Access Feb 5, 2012 at [www.actonel.com/global/prescribing\\_information.pdf](http://www.actonel.com/global/prescribing_information.pdf).
45. Ruggiero SL, Mehrota B. Bisphosphonate-related osteonecrosis of the jaw: diagnosis, prevention and management. *Annu Rev Med* 2009;60:85-96.
46. Bilezikian JP. Osteonecrosis of the jaw: do bisphosphonates pose a risk? *N Engl J Med* 2006;355:2278-81.

47. Boonyapakorn T, Schrimmer I, Reichart PA, Sturm I, Massenkeil G. Bisphosphonate-induced osteonecrosis of the jaws: prospective study of 80 patients with multiple myeloma and other malignancies. *Oral Oncol* 2008;44:857-69.
48. Mavrokki T, Cheng A, Stein B, Gos A. Nature and frequency of bisphosphonate-associated osteonecrosis of the jaws in Australia. *J Oral Maxillofac Surg* 2007;65:415-23.
49. Black DM, Delmas PD, Eastell R, et al. HORIZEN Pivotal Fracture Trial. Once-yearly zoledronic acid for treatment of postmenopausal osteoporosis. *N Engl J Med* 2007;356:1809-22.
50. Etminan M, Aminzadeh K, Matthew IR, Brophy JM. Use of oral bisphosphonates and the risk of aseptic osteonecrosis: a nested case-control study. *J Rheumatol* 2008;35:691-5.
51. Carstos VM, Zhu S, Zavras AI. Bisphosphonate use of the risk of adverse jaw outcomes. *J Am Dent Assoc* 2008;139:23-30.
52. Jeffcoat MK. Safety of oral bisphosphonates: controlled studies on alveolar bone. *Int J Oral Maxillofac Implants* 2006;21:349-53.
53. Nase JB, Suzuki JB. Osteonecrosis of the jaw and oral bisphosphonate treatment. *J Am Dent Assoc* 2006;137:1115-9.
54. American Association of Endodontists position statement, Endodontic Implications of Bisphosphonate-Associated Osteonecrosis of the Jaw. Accessed on Sep 3, 2012 at [www.aae.org/uploadedFiles/Publications\\_and\\_Research/Guidelines\\_and\\_Position\\_Statements/bisphosonatesstatement.pdf](http://www.aae.org/uploadedFiles/Publications_and_Research/Guidelines_and_Position_Statements/bisphosonatesstatement.pdf).

The AAE wishes to thank Dr. Gary G. Goodell for authoring this issue of the newsletter, as well as Dr. Marc Balson for authoring the AAE's Winter 2007 newsletter on this topic. Thanks also to the following article reviewers: Drs. Sidney L. Bourgeois of the American Association of Oral and Maxillofacial Surgeons, James J. Jespersen, James C. Kulild, Robert S. Roda, James F. Wolcott and Susan L. Wolcott.

## AAE Colleagues Online

### Exclusive Bonus Materials

This issue of the *ENDODONTICS: Colleagues for Excellence* newsletter is available online at [www.aae.org/colleagues](http://www.aae.org/colleagues) with the following *exclusive bonus materials*:

- AAE position statement, Endodontic Implications of Bisphosphonate-Associated Osteonecrosis of the Jaw.
- Managing the care of patients receiving antiresorptive therapy for prevention and treatment of osteoporosis. Recommendations from the American Dental Association Council on Scientific Affairs. November 2011.
- American Association of Oral and Maxillofacial Surgeons Position Paper on Bisphosphonate-Related Osteonecrosis of the Jaw – 2009 Update.
- “Ask the Author” Discussion Board for all of your questions and comments

*All back issues* of this newsletter are also available for your ongoing reference online.

### Earn CE With *Colleagues*

With an annual subscription to the AAE Live Learning Center you can earn CE credit for the *ENDODONTICS: Colleagues for Excellence* newsletter series. Visit [www.aae.org/livelearningcenter](http://www.aae.org/livelearningcenter) for more information.




The information in this newsletter is designed to aid dentists. Practitioners must use their best professional judgment, taking into account the needs of each individual patient when making diagnosis/treatment plans. The AAE neither expressly nor implicitly warrants against any negative results associated with the application of this information. If you would like more information, consult your endodontic colleague or contact the AAE.

American Association of Endodontists  
211 E. Chicago Ave., Suite 1100  
Chicago, IL 60611-2691  
[info@aae.org](mailto:info@aae.org) • [www.aae.org](http://www.aae.org)

 [www.facebook.com/endodontists](http://www.facebook.com/endodontists)

 [www.youtube.com/rootcanalspecialists](http://www.youtube.com/rootcanalspecialists)

 @AAENews, @SavingYourTeeth

Did you enjoy this issue of *ENDODONTICS*? Are there topics you would like *ENDODONTICS* to cover in the future? We want to hear from you! Send your comments and questions to the American Association of Endodontists at the address at left.