

ENDODONTICS

*Colleagues for
Excellence*

Fall 2013



Endodontic Diagnosis



Published for the Dental Professional Community by the
American Association of Endodontists

www.aae.org/colleagues

Historically, there have been a variety of diagnostic classification systems advocated for determining endodontic disease (1). Unfortunately, the majority of them have been based upon histopathological findings rather than clinical findings, often leading to confusion, misleading terminology, and incorrect diagnoses (2). A key purpose of establishing a proper pulpal and periapical diagnosis is to determine what clinical treatment is needed (3, 4). For example, if an incorrect assessment is made, then improper management may result. This could include performing endodontic treatment when it is not needed or providing no treatment or some other therapy when root canal treatment is truly indicated. Another important purpose of establishing a universal classification system is to allow for communication between educators, clinicians, students and researchers. A simple and practical system which uses terms related to clinical findings is essential and will help clinicians understand the progressive nature of pulpal and periapical disease, directing them to the most appropriate treatment approach for each condition.

In 2008, the American Association of Endodontists held a consensus conference to standardize diagnostic terms used in endodontics (1). The goals were to propose universal recommendations regarding endodontic diagnoses; develop a standardized definition of key diagnostic terms that will be generally accepted by endodontists, educators, test construction experts, third parties, generalists and other specialists, and students; resolve concerns about testing and interpretation of results; and determine the radiographic criteria, objective test results, and clinical criteria needed to validate the diagnostic terms established at the conference. Both the AAE and the American Board of Endodontics have accepted these terms and recommend their usage across all dental disciplines and health care professions (5, 6, 7). Each of the following diagnostic terms will be defined with typical respective clinical and radiographic characteristics along with representative case examples when appropriate. However, clinicians must recognize that diseases of the pulp and periapical tissues are dynamic and progressive and as such, signs and symptoms will vary depending on the stage of the disease and the patient status. Coupled with this are the limitations associated with current pulp testing modalities as well as clinical and radiographic examination techniques. In order to render proper treatment, a complete endodontic diagnosis must include both a pulpal and a periapical diagnosis for each tooth evaluated.

Examination and Diagnostic Procedures

Endodontic diagnosis is similar to a jigsaw puzzle—diagnosis cannot be made from a single isolated piece of information (4). The clinician must systematically gather all of the necessary information to make a “probable” diagnosis. When taking the medical and dental history, the clinician should already be formulating in his or her mind a preliminary but logical diagnosis, especially if there is a chief complaint. The clinical and radiographic examinations in combination with a thorough periodontal evaluation and clinical testing (pulp and periapical tests) are then used to confirm the preliminary diagnosis (4). In some cases, the clinical and radiographic examinations are inconclusive or give conflicting results and as a result, definitive pulpal and periapical diagnoses cannot be made. It is also important to recognize that treatment should not be rendered without a diagnosis and in these situations, the patient may have to wait and be reassessed at a later date or be referred to an endodontist.

Diagnostic Terminology Approved by the American Association of Endodontists and the American Board of Endodontics (5-7)

Pulpal Diagnoses (9-14)

Normal Pulp is a clinical diagnostic category in which the pulp is symptom-free and normally responsive to pulp testing. Although the pulp may not be histologically normal, a “clinically” normal pulp results in a mild or transient response to thermal cold testing, lasting no more than one to two seconds after the stimulus is removed. One cannot arrive at a probable diagnosis without comparing the tooth in question with adjacent and contralateral teeth. It is best to test the adjacent teeth and contralateral teeth first so that the patient is familiar with the experience of a normal response to cold.

Examination procedures required to make an endodontic diagnosis (8)	
Medical/dental history	Past/recent treatment, drugs
Chief complaint (if any)	How long, symptoms, duration of pain, location, onset, stimuli, relief, referred, medications
Clinical exam	Facial symmetry, sinus tract, soft tissue, periodontal status (probing, mobility), caries, restorations (defective, newly placed?)
Clinical testing: pulp tests	Cold, electric pulp test, heat
periapical tests	Percussion, palpation, Tooth Slooth (biting)
Radiographic analysis	New periapicals (at least 2), bitewing, cone beam-computed tomography
Additional tests	Transillumination, selective anesthesia, test cavity

Reversible Pulpitis is based upon subjective and objective findings indicating that the inflammation should resolve and the pulp return to normal following appropriate management of the etiology. Discomfort is experienced when a stimulus such as cold or sweet is applied and goes away within a couple of seconds following the removal of the stimulus. Typical etiologies may include exposed dentin (dentinal sensitivity), caries or deep restorations. There are no significant radiographic changes in the periapical region of the suspect tooth and the pain experienced is not spontaneous. Following the management of the etiology (e.g. caries removal plus restoration; covering the exposed dentin), the tooth requires further evaluation to determine whether the “reversible pulpitis” has returned to a normal status. Although dentinal sensitivity per se is not an inflammatory process, all of the symptoms of this entity mimic those of a reversible pulpitis.

Symptomatic Irreversible Pulpitis is based on subjective and objective findings that the vital inflamed pulp is incapable of healing and that root canal treatment is indicated. Characteristics may include sharp pain upon thermal stimulus, lingering pain (often 30 seconds or longer after stimulus removal), spontaneity (unprovoked pain) and referred pain. Sometimes the pain may be accentuated by postural changes such as lying down or bending over and over-the-counter analgesics are typically ineffective. Common etiologies may include deep caries, extensive restorations, or fractures exposing the pulpal tissues. Teeth with symptomatic irreversible pulpitis may be difficult to diagnose because the inflammation has not yet reached the periapical tissues, thus resulting in no pain or discomfort to percussion. In such cases, dental history and thermal testing are the primary tools for assessing pulpal status.

Asymptomatic Irreversible Pulpitis is a clinical diagnosis based on subjective and objective findings indicating that the vital inflamed pulp is incapable of healing and that root canal treatment is indicated. These cases have no clinical symptoms and usually respond normally to thermal testing but may have had trauma or deep caries that would likely result in exposure following removal.

Pulp Necrosis is a clinical diagnostic category indicating death of the dental pulp, necessitating root canal treatment. The pulp is non-responsive to pulp testing and is asymptomatic. Pulp necrosis by itself does not cause apical periodontitis (pain to percussion or radiographic evidence of osseous breakdown) unless the canal is infected. Some teeth may be non-responsive to pulp testing because of calcification, recent history of trauma, or simply the tooth is just not responding. As stated previously, this is why all testing must be of a comparative nature (e.g. patient may not respond to thermal testing on any teeth).

Previously Treated is a clinical diagnostic category indicating that the tooth has been endodontically treated and the canals are obturated with various filling materials other than intracanal medicaments. The tooth typically does not respond to thermal or electric pulp testing.

Previously Initiated Therapy is a clinical diagnostic category indicating that the tooth has been previously treated by partial endodontic therapy such as pulpotomy or pulpectomy. Depending on the level of therapy, the tooth may or may not respond to pulp testing modalities.

Apical Diagnoses (9-14)

Normal Apical Tissues are not sensitive to percussion or palpation testing and radiographically, the lamina dura surrounding the root is intact and the periodontal ligament space is uniform. As with pulp testing, comparative testing for percussion and palpation should always begin with normal teeth as a baseline for the patient.

Symptomatic Apical Periodontitis represents inflammation, usually of the apical periodontium, producing clinical symptoms involving a painful response to biting and/or percussion or palpation. This may or may not be accompanied by radiographic changes (i.e. depending upon the stage of the disease, there may be normal width of the periodontal ligament or there may be a periapical radiolucency). Severe pain to percussion and/or palpation is highly indicative of a degenerating pulp and root canal treatment is needed.

Asymptomatic Apical Periodontitis is inflammation and destruction of the apical periodontium that is of pulpal origin. It appears as an apical radiolucency and does not present clinical symptoms (no pain on percussion or palpation).

Chronic Apical Abscess is an inflammatory reaction to pulpal infection and necrosis characterized by gradual onset, little or no discomfort and an intermittent discharge of pus through an associated sinus tract. Radiographically, there are typically signs of osseous destruction such as a radiolucency. To identify the source of a draining sinus tract when present, a gutta-percha cone is carefully placed through the stoma or opening until it stops and a radiograph is taken.

Acute Apical Abscess is an inflammatory reaction to pulpal infection and necrosis characterized by rapid onset, spontaneous pain, extreme tenderness of the tooth to pressure, pus formation and swelling of associated tissues. There may be no radiographic signs of destruction and the patient often experiences malaise, fever and lymphadenopathy.

Condensing Osteitis is a diffuse radiopaque lesion representing a localized bony reaction to a low-grade inflammatory stimulus usually seen at the apex of the tooth.

Diagnostic Case Examples

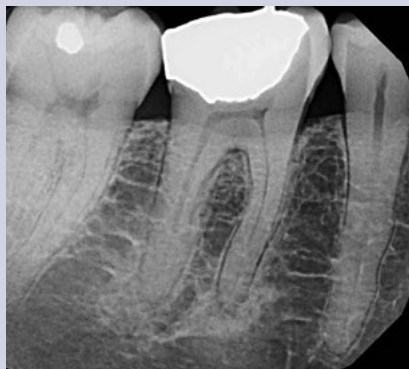

Fig. 1. Mandibular right first molar had been hypersensitive to cold and sweets over the past few months but the symptoms have subsided. Now there is no response to thermal testing and there is tenderness to biting and pain to percussion. Radiographically, there are diffuse radiopacities around the root apices. **Diagnosis: Pulp necrosis; symptomatic apical periodontitis with condensing osteitis.** Non-surgical endodontic treatment is indicated followed by a build-up and crown. Over time the condensing osteitis should regress partially or totally (15).

Fig. 1.

Fig. 2. Following the placement of a full gold crown on the maxillary right second molar, the patient complained of sensitivity to both hot and cold liquids; now the discomfort is spontaneous. Upon application of Endo-Ice® on this tooth, the patient experienced pain and upon removal of the stimulus, the discomfort lingered for 12 seconds. Responses to both percussion and palpation were normal; radiographically, there was no evidence of osseous changes. **Diagnosis: Symptomatic irreversible pulpitis; normal apical tissues.** Non-surgical endodontic treatment is indicated; access is to be repaired with a permanent restoration. Note that the maxillary second premolar has severe distal caries; following evaluation, the tooth was diagnosed with **symptomatic irreversible pulpitis (hypersensitive to cold, lingering eight seconds); symptomatic apical periodontitis (pain to percussion).**

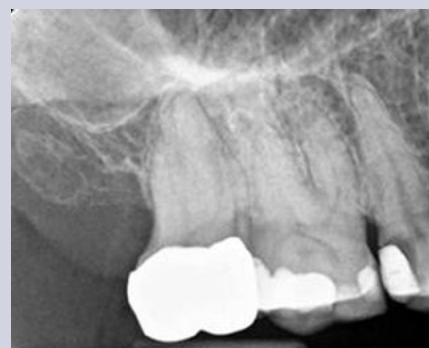

Fig. 2.

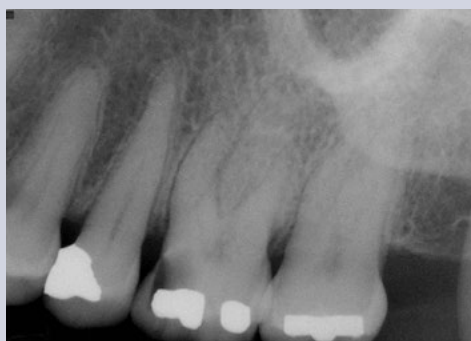

Fig. 3. Maxillary left first molar has occlusal-mesial caries and the patient has been complaining of sensitivity to sweets and to cold liquids. There is no discomfort to biting or percussion. The tooth is hyper-responsive to Endo-Ice® with no lingering pain. **Diagnosis: reversible pulpitis; normal apical tissues.** Treatment would be excavation of the caries followed by placement of a permanent restoration. If the pulp is exposed, treatment would be non-surgical endodontic treatment followed by a permanent restoration such as a crown.

Fig. 3.

Fig. 4. Mandibular right lateral incisor has an apical radiolucency that was discovered during a routine examination. There was a history of trauma more than 10 years ago and the tooth was slightly discolored. The tooth did not respond to Endo-Ice® or to the EPT; the adjacent teeth responded normally to pulp testing. There was no tenderness to percussion or palpation in the region. **Diagnosis: pulp necrosis; asymptomatic apical periodontitis.** Treatment is non-surgical endodontic treatment followed by bleaching and permanent restoration.

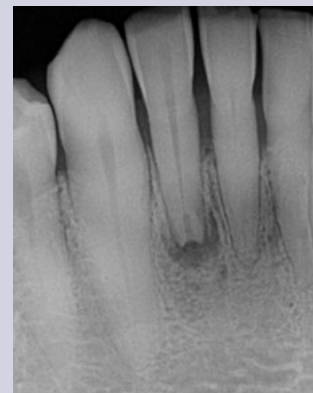


Fig. 4.

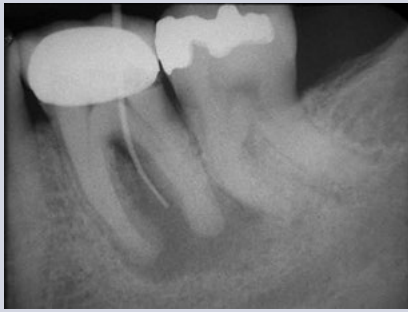

Fig. 5.

Fig. 5. Mandibular left first molar demonstrates a relatively large apical radiolucency encompassing both the mesial and distal roots along with furcation involvement. Periodontal probing depths were all within normal limits. The tooth did not respond to thermal (cold) testing and both percussion and palpation elicited normal responses. There was a draining sinus tract on the mid-facial of the attached gingiva which was traced with a gutta-percha cone. There was recurrent caries around the distal margin of the crown. **Diagnosis: pulp necrosis; chronic apical abscess.** Treatment is crown removal, non-surgical endodontic treatment and placement of a new crown.

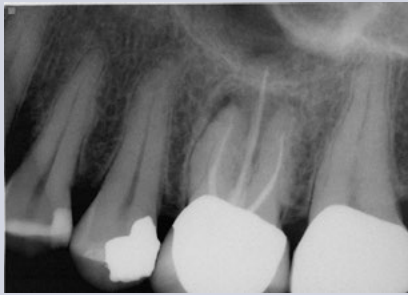

Fig. 6.

Fig. 6. Maxillary left first molar was endodontically treated more than 10 years ago. The patient is complaining of pain to biting over the past three months. There appear to be apical radiolucencies around all three roots. The tooth was tender to both percussion and to the Tooth Slooth®. **Diagnosis: previously treated; symptomatic apical periodontitis.** Treatment is nonsurgical endodontic retreatment followed by permanent restoration of the access cavity.

Fig. 7. Maxillary left lateral incisor exhibits an apical radiolucency. There is no history of pain and the tooth is asymptomatic. There is no response to Endo-Ice® or to the EPT, whereas the adjacent teeth respond normally to both tests. There is no tenderness to percussion or palpation. **Diagnosis: pulp necrosis; asymptomatic apical periodontitis.** Treatment is nonsurgical endodontic treatment and placement of a permanent restoration.

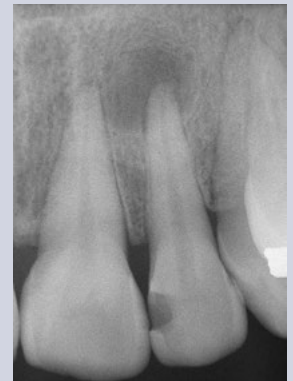

Fig. 7.

References

1. Glickman GN. AAE consensus conference on diagnostic terminology: background and perspectives. *J Endod* 2009;35:1619.
2. Seltzer S, Bender IB, Ziontz M. The dynamics of pulp inflammation: correlations between diagnostic data and actual histologic findings in the pulp. *Oral Surg Oral Med Oral Pathol* 1963;16:846-71;969-77.
3. Berman LH, Hartwell GR. Diagnosis. In: Cohen S, Hargreaves KM, eds. *Pathways of the Pulp*, 11th ed. St. Louis, MO: Mosby/Elsevier; 2011:2-39.
4. Schweitzer JL. The endodontic diagnostic puzzle. *Gen Dent* 2009; Nov/Dec. 560-7.
5. AAE Consensus Conference Recommended Diagnostic Terminology. *J Endod* 2009;35:1634.
6. American Association of Endodontists. *Glossary of Endodontic Terms*. 8th ed. 2012.
7. Glickman GN, Bakland LK, Fouad AF, Hargreaves KM, Schwartz SA. Diagnostic terminology: report of an online survey. *J Endod* 2009;35:1625.
8. Abbott PV, Yu C. A clinical classification of the status of the pulp and the root canal system. *Aust Dent J* 2007;52 (Endod Suppl):S17-31.
9. Jafarzadeh H, Abbott PV. Review of pulp sensibility tests. Part 1: general information and thermal tests. *Int Endod J* 2010;43:738-62.
10. Jafarzadeh H, Abbott PV. Review of pulp sensibility tests. Part II: electric pulp tests and test cavities. *Int Endod J* 2010;43:945-58.
11. Newton CW, Hoen MM, Goodis HE, Johnson BR, McClanahan SB. Identify and determine the metrics, hierarchy, and predictive value of all the parameters and/or methods used during endodontic diagnosis. *J Endod* 2009;35:1635.
12. Levin LG, Law AS, Holland GR, Abbot PV, Roda RS. Identify and define all diagnostic terms for pulpal health and disease states. *J Endod* 2009;35:1645.
13. Gutmann JL, Baumgartner JC, Gluskin AH, Hartwell GR, Walton RE. Identify and define all diagnostic terms for periapical/periradicular health and disease states. *J Endod* 2009;35:1658.
14. Rosenberg PA, Schindler WG, Krell KV, Hicks ML, Davis SB. Identify the endodontic treatment modalities. *J Endod* 2009;35:1675.
15. Green TL, Walton RE, Clark JM, Maixner D. Histologic examination of condensing osteitis in cadaver specimens. *J Endod* 2013; 39:977-9.

The AAE wishes to thank Drs. Gerald N. Glickman and Jordan L. Schweitzer for authoring this issue of the newsletter, as well the following article reviewers: Drs. Peter J. Babick, Gary R. Hartwell, Terryl A. Propper and Martin J. Rogers.



www.aae.org/livelearningcenter

Exclusive Online Bonus Materials: Endodontic Diagnosis

This issue of the *Colleagues* newsletter is available online at www.aae.org/colleagues with the following *exclusive bonus materials*:

- Full-Text Article: Glickman GN. AAE consensus conference on diagnostic terminology: background and perspectives. *J Endod* 2009;35:1619.
- Full-Text Article: AAE Consensus Conference Recommended Diagnostic Terminology. *J Endod* 2009;35:1634.
- American Association of Endodontists Glossary of Endodontic Terms

Earn CE Online With *Colleagues*

With an annual subscription to the **AAE Live Learning Center**, you can earn CE credit online for the *ENDODONTICS: Colleagues for Excellence* newsletter series and much more. Visit www.aae.org/livelearningcenter today.

The information in this newsletter is designed to aid dentists. Practitioners must use their best professional judgment, taking into account the needs of each individual patient when making diagnosis/treatment plans. The AAE neither expressly nor implicitly warrants against any negative results associated with the application of this information. If you would like more information, consult your endodontic colleague or contact the AAE.

Did you enjoy this issue of Colleagues? Are there topics you would like to cover in the future? We want to hear from you! Send your comments and questions to the American Association of Endodontists at the address below, and visit the Colleagues online archive at www.aae.org/colleagues for back issues of the newsletter.



©2013, American Association of Endodontists
211 E. Chicago Ave., Suite 1100
Chicago, IL 60611-2691

Phone: 800/872-3636 (U.S., Canada, Mexico) or 312/266-7255
Fax: 866/451-9020 (U.S., Canada, Mexico) or 312/266-9867

Email: info@aae.org Website: www.aae.org



www.facebook.com/endodontists



@aaenews / @savingyourteeth



www.youtube.com/rootcanalspecialists