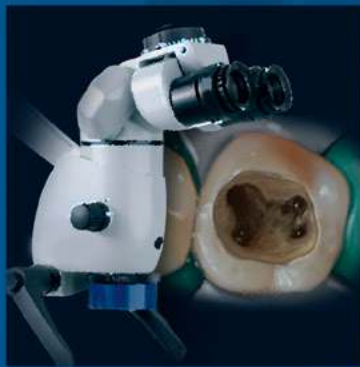

# ENDODONTICS



*Colleagues for  
Excellence*

Winter 2016

*The Dental Operating Microscope  
in Endodontics*



Published for the Dental Professional Community by the  
***American Association of Endodontists***

[www.aae.org/colleagues](http://www.aae.org/colleagues)

The practice of endodontics requires precision and great attention to detail. These depend on the training, skills and experience of the clinician. Most endodontic procedures are carried out in dark and confined places, and fractions of millimeters may decide the outcome of treatment. Over the past decades, endodontics has gained not only basic and clinical scientific knowledge, but also has taken technological quantum leaps. Due to the intricate nature of endodontic treatment, practitioners have always sought to improve their vision of the operational field.

### **Advantages of Dental Microscopes**

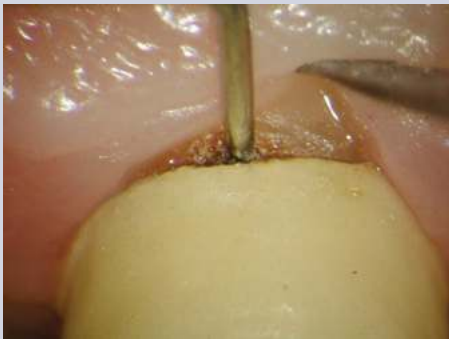Better vision requires enhanced magnification and illumination, and both microscopes and loupes have been widely adopted. Operating microscopes have a number of advantages compared to loupes. Loupes are worn on the head and may be used with or without external light sources. This necessitates weight limitations and restricts the oculars to the bare minimum of lenses needed for magnification. By contrast, the microscope is a self-supported unit; therefore, additional lenses or prisms are not a concern. This has meaningful implications with regard to ergonomics and visualization.

The attachment of loupes to glasses dictates a design that angles the binoculars inward in order for the viewer to focus on the object. As a result, the practitioner's eyes also rotate medially. This is similar to near object accommodation by the naked eye which can lead to eye muscle strain and fatigue. By contrast, microscope binoculars are arranged in a parallel orientation. This arrangement is facilitated by prisms that let the incoming light beams reach the eyes also in a parallel direction. This simulates the observation of a distant object: a straight, forward-looking gaze that causes less muscle stress and fatigue. In addition, from an ergonomic perspective, working correctly with a dental microscope improves overall body posture and may reduce neck and back pain.

Commercially available microscopes provide adjustable magnification ranging from approximately 4x-25x magnification, while most loupes provide fixed magnification between 2.5x-6x. Magnification can be divided in low magnification (~2x-8x), mid magnification (~8x-16x), and high magnification (~16x-25x). Low, mid and high magnification are applicable for different procedural steps throughout nonsurgical and surgical endodontic treatment. Low magnification is mainly applicable for an overview of the operating field. Mid magnification is used for the main procedural steps throughout root canal therapy and endodontic surgery. High magnification is used for the identification of minute structures and documentation of the finest details. Using a microscope significantly increases a practitioner's accuracy (1). However, it must be mentioned that there is a learning curve and working at both mid and high magnification will require the practitioner to slow down movements to avoid unintended actions on the smallest of anatomical structures. As a result of working in a small-scale environment, new types of micro-instruments also were introduced to the dental profession.

### **History of Microscopes in Endodontics**

The idea of using microscopes in dentistry is not new. Bowles suggested and used a dental microscope as early as 1907 (2)! In endodontics, dental operating microscopes were first introduced by individual clinicians (3, 4) and then adopted by endodontic specialty programs throughout the United States. The AAE was an early proponent of training in microscopes for endodontic residents and successfully advocated for the Commission on Dental Accreditation to include a microscope proficiency standard to the CODA educational standards for postgraduate endodontic programs in 1998. The latest standard requires the teaching of magnification devices "beyond that of magnifying eyewear" at an in-depth level, which is the highest of the levels of knowledge prescribed by CODA (5). Based on two surveys in 1999 and 2008, the accessibility and use of the microscope by endodontists increased from 52% to 90% (6, 7). It is now also increasingly being used by other specialties (8) and in dental education (9).



*Fig. 1.* High-magnification inspection of caries below crown margin (courtesy Dr. Francesco Maggiore, Aschaffenburg, Germany).

### **Microscope Use for Nonsurgical Procedures**

For the endodontic practitioner, the dental microscope is useful for diagnosis and clinical procedures. The microscope may aid diagnostically in identifying caries, insufficient crown or restorative filling margins (Figure 1), or assessing craze or fracture lines. During root canal therapy, magnification and illumination provided by the operating microscope aids with caries removal,

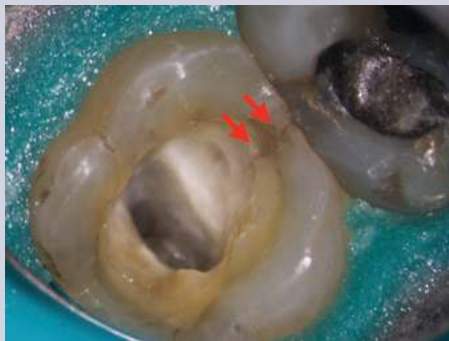

Fig. 2. Evaluation of extent of mesial fracture line (arrows) in left second maxillary molar. Microscopic inspection confirmed restorability.

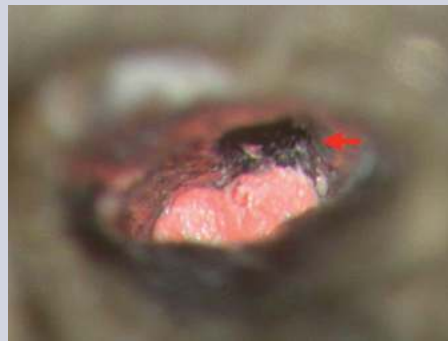

Fig. 3. Deep canal bifurcation. Microscope-controlled filling of first canal just below split (arrow).

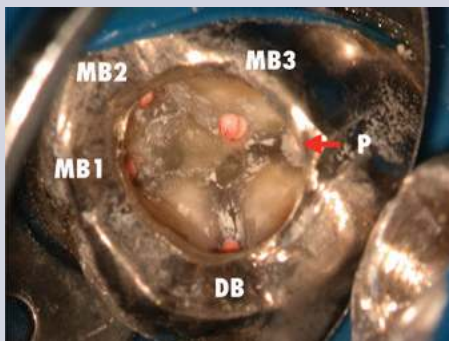


Fig. 4a. Situation after irreversible pulpitis of left maxillary first molar two weeks after delivery of fixed partial denture. High magnification allowed for identification and treatment of three mesio-buccal canals through existing restoration.

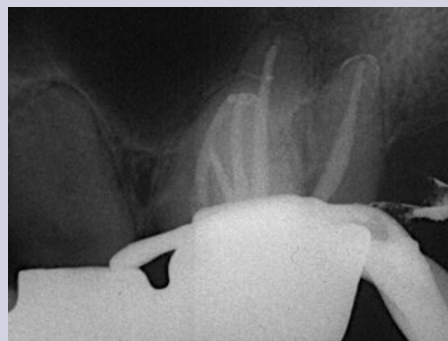

Fig. 4b. Post-operative radiograph.

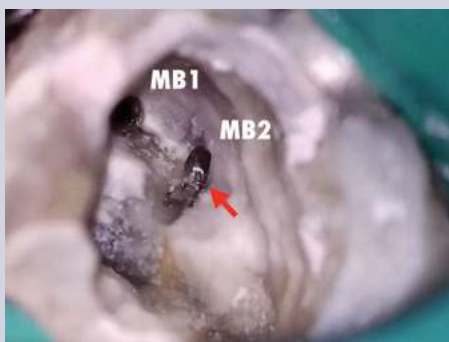

Fig. 5a. Separated instrument in second mesio-buccal canal of left maxillary first molar (arrow). Situation after uncovering of fragment with ultrasonic tips and debris removal.

access preparation, removal of pulp chamber calcifications, identification of root canal orifices, identification of cracks and fracture lines (Figure 2), and the treatment of internal resorptions. Under the microscope, subtle changes in dentin color and texture become apparent, such as developmental lines on the pulp floor guiding the practitioner towards root canal orifices, or the darker color of the pulp floor itself, allowing the practitioner safer dentin removal.

High magnification can help in the localization and instrumentation of obstructed and calcified canals, the identification of canal bifurcations (Figure 3), the removal of canal obstructions such as denticles and calcifications, and obturation (Figure 4). Additional primary endodontic procedures benefitting from microscope use include vital pulp therapy and regenerative endodontics by allowing careful and gentle manipulation of the pulpal tissues or a blood clot, respectively. Enhanced vision also aids

in the treatment of dental anomalies, such as *dens invaginatus*, or fused teeth.

In endodontic retreatments, the microscope is helpful in identifying and removing leftover filling materials, such as sealer remnants, pastes or gutta-percha (10), silver points and carrier-based materials, posts or fractured instruments (11) (Figure 5). It also aids in nonsurgical perforation repair, allowing the practitioner to clean the perforation site and place the perforation repair material more precisely (12, 13).

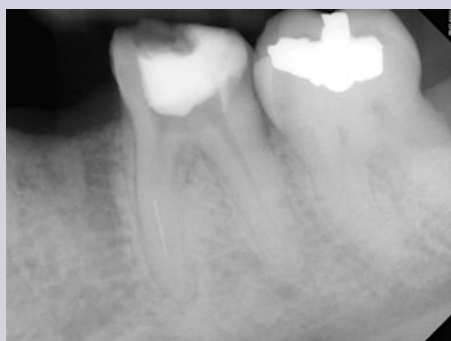### **Microscope Use for Surgical Procedures**

Surgical endodontics has been completely transformed by microscopic procedures. For many years surgical burs and amalgam for root-end fillings were the standard of care. The incorporation of the microscope, and also to a certain degree the endoscope, together with the use of ultrasonic tips and biocompatible filling materials, has evolved the classical apicoectomy into modern endodontic

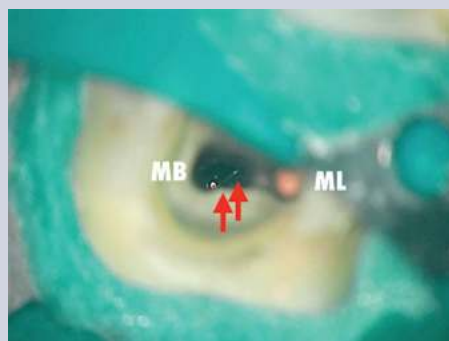
microsurgery (14). All steps of endodontic microsurgery are carried out under varying degrees of magnification, including flap preparation, osteotomy, identification of root apices, root-end resection, inflammatory tissue removal, observation of the resected root surface (Figure 6), root-end preparation, root-end filling, and suturing (15). The microscope is also helpful for cervical or external resorption or perforation repairs.

### **Treatment Effects**

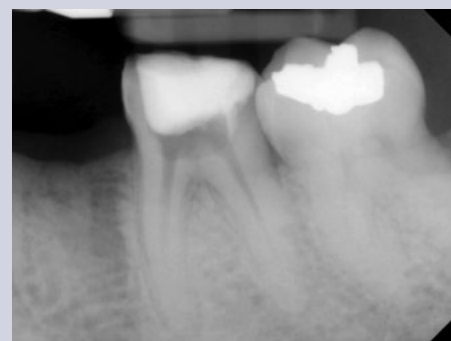There has been great debate over whether the use of magnification would actually increase the success rate of endodontic procedures. It is an accepted fact in endodontics that microbes and their endotoxins are responsible for the majority of inflammatory periapical lesions. Healing of these lesions in cases of a diagnosis of pulp necrosis has been associated with



**Fig. 5b.** Pre-operative radiograph. Fractured instrument in mesial root of lower left first molar. Patient was referred for fragment removal and continuation of treatment.

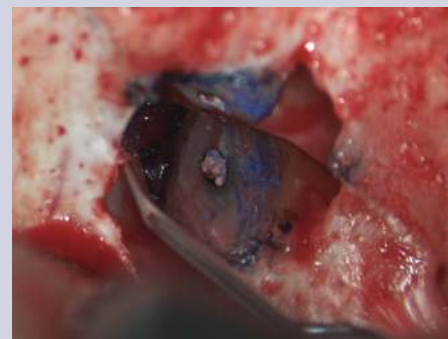

**Fig. 5c.** Access to instrument fragment (arrows) in mesiobuccal canal using ultrasonic tips. Note loosely placed gutta-percha in mesiolingual canal to prevent any fragments or debris from accidentally blocking the canal.



**Fig. 5d.** Radiograph verifying complete instrument removal. Temporary after first appointment. Canals are filled with non-radiopaque calcium hydroxide.

disinfection of the root canal system, reduction of the microbial content, filling of the root canal system and the permanent restoration of the tooth. It is thus assumed that the identification and treatment of all parts of the root canal system increase the chances of a successful treatment and good long-term prognosis. Ample literature has been published with regard to the identification of additional canals with the help of higher magnification and illumination (16, 17). The effectiveness of vision enhancement for the detection of second mesio-buccal canals (MB2) in maxillary molars was assessed both *in vitro* and *in vivo*. The detection rate of MB2 canals *in vitro* was shown to be 90% with the operating microscope and 52% without aided vision. Gorduysus et al. (18) demonstrated that the percentage of MB2 canal negotiation increased with the aid of higher magnification. Burley et al. (19) described the successful identification of MB2s in 312 maxillary first and second molars in 57.4% of the cases when using the operating microscope, 55.3% with dental loupes and 18.2% with unaided vision. In first maxillary molars, the incidences of MB2 identification were 71.1%, 62.5% and 17.2%, for the microscope, dental loupes and no magnification groups, respectively. Stropko (20) treated a total 1,732 maxillary molars working at times with unaided vision and at times with a dental microscope. With more experience and a dental microscope, the incidence of locating MB2 canals increased from 73.2% to 93.0% in first molars and from 50.7% to 60.4% in second molars. Microscope use also increased the number of root canal orifices located in mandibular molars (21), and significantly increased the quality of access cavity preparation and the accuracy of canal identification when treatment was performed by dental students recently instructed in microscope use (22).



**Fig. 6.** High-magnification inspection of resected root surface of left maxillary lateral incisor using a micro-mirror. Note leakage of previous root filling stained with methylene blue.

### **Nonsurgical Treatment Outcomes**

It was long uncertain if microscope usage resulted in improvements in nonsurgical treatment outcomes. Del Fabbro et al. conducted two Cochrane Reviews, in 2009 (23) and 2015 (24), to identify randomized controlled trials and quasi-randomized controlled trials comparing endodontic therapy performed with or without one or more magnification devices. Neither in 2009, nor in 2015, were the authors able to identify a single study reporting the outcome of either nonsurgical or surgical endodontic therapy matching the strict criteria put forward in their study. Hence, the authors concluded that it was unknown if and how any magnification device affected the treatment outcome, in particular, since a great number of factors besides the microscope can have a significant impact on the success of endodontic procedures. The authors suggested future long-term, well-designed randomized clinical trials. Recently, however, a study published by Monea et al. (25) assessed the impact of the operating microscope on the outcome of nonsurgical treatments of a consecutive series of 184 comparable teeth diagnosed with pulp necrosis and chronic apical periodontitis performed by postgraduate students. Success was defined as a decrease or disappearance of the radiolucency following the recommendations of the European Society of Endodontology. After follow-up periods of six months and 18 months there were significant differences between microscope and control groups, with 94.8% versus 87.5% (healed and improved) at six months, and 95.9% and 91.9% at 18 months. At 18 months, 89% of cases available for follow-up in the microscope group were classified as completely healed.

### **Surgical Treatment Outcomes**

Another systematic review by del Fabbro et al. (26) to investigate the use of magnification devices in endodontics identified three prospective clinical trials evaluating the outcomes of endodontic surgery. The authors were unable to identify significant differences in outcomes depending on treatment with loupes, microscope or an endoscope and suggested that different magnification devices could only minimally affect the outcome. In two meta-analyses, Setzer et al. described the differences in outcome of three techniques for endodontic surgery (27, 28). Investigated were clinical studies that applied traditional endodontic surgical techniques (TRS), including 12 studies with a total sample size of 925 teeth using no magnification, straight surgical handpieces and amalgam root-end filling and a cumulative success rate of 59.0%; seven studies using contemporary surgical procedures (CRS) with a collective sample size of 610 teeth, employing magnifying loupes, ultrasonic root-end preparation and biocompatible filling materials and a cumulative success rate of 88.1%; and nine studies on endodontic microsurgery (EMS) with a total of 699 teeth using the identical techniques as CRS with the only differences being the use of high-power magnification devices such as microscopes or endoscopes instead of loupes and a cumulative success rate of 93.5%. The cumulative success rate of the EMS group was significantly higher than the CRS group, which only employed loupes, and the TRS group, which used no magnification. The EMS group combined studies that employed both the dental microscope and the endoscope. It needs to be mentioned that these studies are comparable as both microscopes and endoscopes provide high-power magnification and illumination and also because the microscope is used for the majority of the steps of the surgical procedure in the studies where an endoscope was used during root-end preparation. The endodontic microsurgery procedures demonstrated significantly better cumulative success rates than the studies that only employed loupes when all 16 studies with a total of 1309 teeth were compared. Seven of 16 studies provided information on the individual tooth type (four for CRS and three for EMS), demonstrating a significant difference in probability of success between the groups for molars. Tsesis et al. (29) provided an updated systematic review on endodontic surgery in 2013 and also confirmed a statistically significant difference in successful outcomes of both microscope and endoscope-assisted procedures compared to loupes.

### **Microscope Features and Upgrades**

Modern dental microscopes have evolved considerably with regard to features and options available to the dental clinician. Depending on personal preferences and possible locations in the operatory, floor-standing, wall- or ceiling-mounted units are available. While standard microscopes come with basic optics and light options, certain accessory features are recommended for endodontic purposes. Surgical procedures will require greater angulations to view resected root surfaces and other surgical details. At a minimum, a microscope should be equipped with 180°-tiltable binoculars to address the angulation requirements and an eyepiece with a reticle. A reticle is a set of fine lines, most commonly in the shape of cross-hairs or concentric rings, that provides proper centering on the object in focus and allows for easier individual calibration (parfocaling) of the microscope. It also is an indispensable tool for documentation. Since light and the object image reach the binoculars virtually free of shadows, microscope photography and recording allow for excellent image quality for documentation and clinical operations. However, this requires perfect calibration with an external monitor and a reticle to center the image. Full high-definition and three-chip cameras are the gold standard for video recording and available as external or internal solutions. Screenshots from video recordings can be obtained at higher quality by using post-processing software applications that allow for image stacking (30). For still photography new generation digital mirrorless cameras have demonstrated advantages compared to DSLRs.

There is a variety of additional upgrades for core microscope functions. Instead of fixed focal distances that limit the microscope to an object distance of 200 mm, 250 mm or 300 mm, variable focal distance adapters have become available, allowing for easier switching between practitioners and easier adjustment to patients of different statures. These are offered in top-of-the-line microscopes, often in conjunction with electrical zoom and fine focus options that allow smooth and stepless adjustments of both magnification and focus. Extendable (foldable) binoculars were introduced for better ergonomics. Magnetic arrest functions (clutch) are available for increased stability, particularly for microscopes with several documentation ports and attachments. The practitioner can choose from a variety of light sources. The traditional standard is still halogen (yellowish hue, peak at 600-700 nm, ~3300K) and the brightest option is xenon (like daylight, homogeneous spectrum 400-700 nm, ~5500K), making it most useful for the identification of fine details in deeper areas of the root canal system and documentation. Recently LED lights (green part of emission spectrum, low at 450 nm and 550 nm, ~5700K) became available and offer a significantly longer lifetime, however, at a reduced brightness compared to xenon.

## **Conclusion**

The dental operating microscope has become an integral part of endodontic practice. For both nonsurgical and surgical endodontic therapy it is indispensable for excellency. Besides the obvious benefits for clinical practice, evidence has become available that demonstrates better outcomes compared to treatment without vision enhancement or magnifying eyewear. Treatment rendered using the dental operating microscope results in superior care for patients, and modern endodontic therapy is more effective because of its use.

---

## **References**

1. Bowers DJ, Glickman GN, Solomon ES, He J. Magnification's effect on endodontic fine motor skills. *J Endod.* 2010;36:1135-8.
2. Bowles SW. A New Adaptation of the Microscope to Dentistry. *Dental Cosmos* 1907;49:358-62
3. Carr G. Microscopes in endodontics. *Calif Dent Assoc J* 1992;11:55-61.
4. Pecora G, Andreana S. Use of dental operation microscope in endodontic surgery. *Oral Surg Oral Med Oral Pathol* 1993;75:751-8.
5. AAE Special Committee to Develop a Microscope Position Paper. AAE Position Statement. Use of microscopes and other magnification techniques. *J Endod* 2012;38:1153-5.
6. Mines P, Loushine RJ, West LA, Liewehr FR, Zadinsky JR. Use of the microscope in endodontics: a report based on a questionnaire. *J Endod* 1999;25:755-8.
7. Kersten DD, Mines P, Sweet M. Use of the microscope in endodontics: results of a questionnaire. *J Endod.* 2008;34:804-7.
8. Mamoun JS. A rationale for the use of high-powered magnification or microscopes in general dentistry. *Gen Dent* 2009;57:18-26.
9. Knowles KI, Ibarrola JL, Ludlow MO. The dental operating microscope as an educational tool. *J Dent Educ.* 1998;62:429-31.
10. Baldassari-Cruz LA, Wilcox LR. Effectiveness of gutta-percha removal with and without the microscope. *J Endod* 1999;25:627-8.
11. Fu M, Zhang Z, Hou B. Removal of broken files from root canals by using ultrasonic techniques combined with dental microscope: a retrospective analysis of treatment outcome. *J Endod.* 2011;37:619-22.
12. Daoudi MF. Microscopic management of endodontic procedural errors: perforation repair. *Dent Update.* 2001;28:176-80.
13. Krupp C, Bargholz C, Brüsehaber M, Hülsmann M. Treatment outcome after repair of root perforations with mineral trioxide aggregate: a retrospective evaluation of 90 teeth. *J Endod.* 2013;39:1364-8.
14. Rubinstein RA, Kim S. Short-term observation of the results of endodontic surgery with the use of a surgical operation microscope and Super-EBA as root-end filling material. *J Endod.* 1999;43-48.
15. Kim S, Kratchman S. Modern endodontic surgery concepts and practice: a review. *J Endod.* 2006;32:601-23.
16. de Carvalho MC, Zuolo ML. Orifice locating with a microscope. *J Endod.* 2000;26:532-4.
17. Cabral dos Santos Accioly Lins C, Verçosa de Melo Silva EM, Agnelo de Lima G, Acioly Conrado de Menezes SE, Coelho Travassos RM. Operating microscope in endodontics: A systematic review. *Open Journal of Stomatology.* 2013:1-5
18. Görduysus MO, Görduysus M, Friedman S. Operating microscope improves negotiation of second mesiobuccal canals in maxillary molars. *J Endod.* 2001;27:683-6.
19. Bührley LJ, Barrows MJ, BeGole EA, Wenckus CS. Effect of magnification on locating the MB2 canal in maxillary molars. *J Endod* 2002;28:324-7.
20. Stropko JJ. Canal morphology of maxillary molars: clinical observations of canal configurations. *J Endod* 1999;25:446-50.
21. Karapinar-Kazandag M, Basrani BR, Friedman S. The operating microscope enhances detection and negotiation of accessory mesial canals in mandibular molars. *J Endod.* 2010;36:1289-94.
22. Rampado ME, Tjaderhane L, Friedman S, Hamstra SJ. The benefit of the operating microscope for access cavity preparation by undergraduate students. *J Endod* 2004:863-7.
23. Del Fabbro M, Taschieri S, Lodi G, Banfi G, Weinstein RL. Magnification devices for endodontic therapy. *Cochrane Database Syst Rev.* 2009;8:CD005969.
24. Del Fabbro M, Taschieri S, Lodi G, Banfi G, Weinstein RL. Magnification devices for endodontic therapy. *Cochrane Database Syst Rev.* 2015;12:CD005969.

## ENDODONTICS: *Colleagues for Excellence*

25. Monea M, Hantoiu T, Stoica A, Sita D, Sitaru A. The impact of operating microscope on the outcome of endodontic treatment performed by postgraduate students. *Eur Sci J.* 2015;305-11.
26. Del Fabbro M, Taschieri S. Endodontic therapy using magnification devices: a systematic review. *J Dent.* 2010;38:269-75.
27. Setzer FC, Shah S, Kohli M, Karabucak B, Kim S. Outcome Of Endodontic Surgery: A Meta-Analysis Of The Literature - Part 1: Comparison Of Traditional Root- End Surgery And Endodontic Microsurgery. *J Endod.* 2010;36:1757-1765.
28. Setzer FC, Kohli M, Shah S, Karabucak B, Kim S. Outcome of Endodontic Surgery: A Meta-analysis of the Literature - Part 2: Comparison of Endodontic Microsurgical Techniques With and Without the Use of Higher Magnification. *J Endod.* 2012;38:1-10.
29. Tsesis I, Rosen E, Taschieri S, Telishevsky Strauss Y, Ceresoli V, Del Fabbro M. Outcomes of surgical endodontic treatment performed by a modern technique: an updated meta-analysis of the literature. *J Endod.* 2013;39:332-9.
30. Suehara M, Nakagawa K, Aida N, Ushikubo T, Morinaga K. Digital video image processing from dental operating microscope in endodontic treatment. *Bull Tokyo Dent Coll* 2012;53:27-31.

The AAE wishes to thank Dr. Frank C. Setzer for authoring this issue of the newsletter, as well the following article reviewers: Drs. Jeffrey S. Albert, Mark B. Desrosiers, Steven J. Katz, Garry L. Myers and Terryl A. Propper.

### Exclusive Online Bonus Materials: The Dental Operating Microscope in Endodontics

This issue of the *Colleagues* newsletter is available online at [www.aae.org/colleagues](http://www.aae.org/colleagues) with the following *exclusive bonus materials*:

- Full-Text Article: Monea M, Hantoiu T, Stoica A, Sita D, Sitaru A. The impact of operating microscope on the outcome of endodontic treatment performed by postgraduate students. *Eur Sci J.* 2015;305-11
- Full-Text Article: Setzer FC, Shah S, Kohli M, Karabucak B, Kim S. Outcome Of Endodontic Surgery: A Meta-Analysis Of The Literature - Part 1: Comparison Of Traditional Root- End Surgery And Endodontic Microsurgery. *J Endod.* 2010;36:1757-1765
- Full-Text Article: Setzer FC, Kohli M, Shah S, Karabucak B, Kim S. Outcome of Endodontic Surgery: A Meta-analysis of the Literature - Part 2: Comparison of Endodontic Microsurgical Techniques With and Without the Use of Higher Magnification. *J Endod.* 2012;38:1-10



**LIVE LEARNING CENTER** *Endodontic education online, on demand.*

Earn online CE credit when you enjoy two articles from **Colleagues for Excellence!**  
[www.aae.org/LiveLearningCenter](http://www.aae.org/LiveLearningCenter)

## Endodontic Case Study

This new feature in *Colleagues for Excellence* highlights endodontic treatment that demonstrates the benefits of treatment planning and partnership with an endodontist to improve patient outcomes.

Mandibular right first molar. Nonsurgical root canal treatment had been completed five years ago. Originally, a new crown restoration had been planned. However, the periapical radiograph revealed periradicular radiolucencies (periapical and in the furcation area) (Figure 1). The patient received a recommendation to extract the tooth due to the bone loss in the furcation. There were no symptoms and periodontal probing depths were within normal limits, suggesting an endodontic problem as the origin of the furcation defect. Nonsurgical retreatment was initiated. The clinical image shows the previously treated four canals with infected gutta-percha filling (Figure 2). Under high magnification, a furcation canal (Figure 3, arrow) and a third distal canal (Figure 4) were located. The post-operative radiograph shows the retreated tooth with five main canals (Figure 5). The one-year follow-up radiograph demonstrates the complete resolution of the periradicular radiolucencies and permanent restoration of the tooth (Figure 6).

Contributed by Dr. Frank C. Setzer

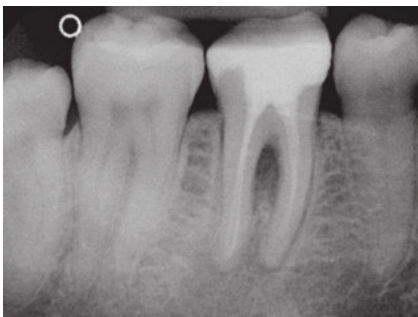

Fig. 1. Pre-op image

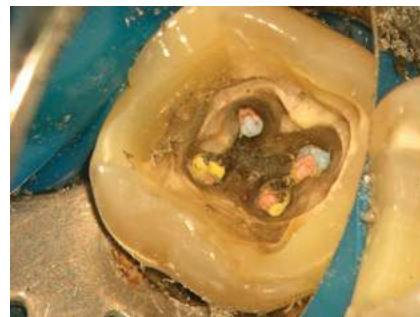

Fig. 2. Clinical image

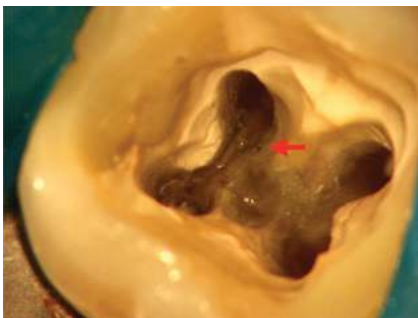


Fig. 3. Clinical image

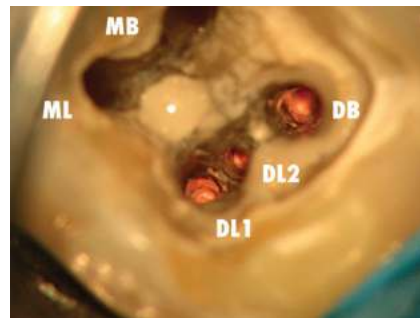


Fig. 4. Clinical image

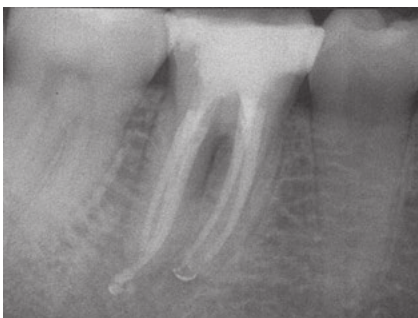


Fig. 5. Post-op image

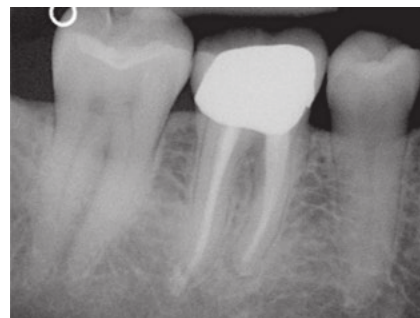

Fig. 6. One-year recall image

Information in this newsletter is designed to aid dentists. Practitioners must use their best professional judgment, taking into account the needs of each individual patient when making diagnosis/treatment plans. The AAE neither expressly nor implicitly warrants against any negative results associated with the application of this information. If you would like more information, consult your endodontic colleague or contact the AAE.

Did you enjoy this issue of *Colleagues*? Are there topics you would like to cover in the future? We want to hear from you! Send your comments and questions to the American Association of Endodontists at the address below, and visit the *Colleagues* online archive at [www.aae.org/colleagues](http://www.aae.org/colleagues) for back issues of the newsletter.



©2016, American Association of Endodontists  
211 E. Chicago Ave., Suite 1100  
Chicago, IL 60611-2691

Phone: 800/872-3636 (U.S., Canada, Mexico) or 312/266-7255  
Fax: 866/451-9020 (U.S., Canada, Mexico) or 312/266-9867

Email: [info@aae.org](mailto:info@aae.org) Website: [www.aae.org](http://www.aae.org)



[www.facebook.com/endodontists](https://www.facebook.com/endodontists)

[@savingyourteeth](https://twitter.com/savingyourteeth)

[www.youtube.com/rootcanalspecialists](https://www.youtube.com/rootcanalspecialists)