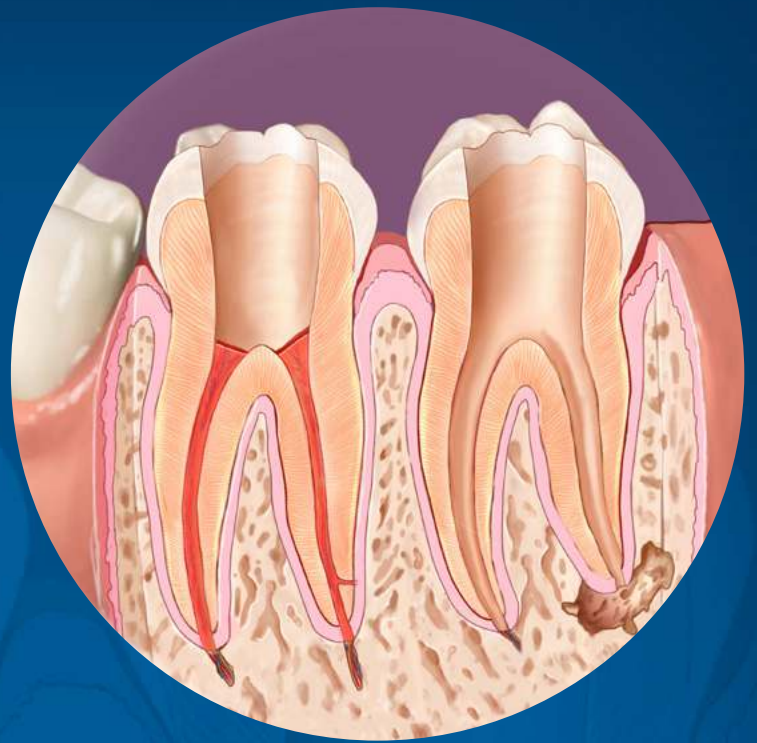

# Management of Endodontic Emergencies: Pulpotomy Versus Pulpectomy

Fall 2017



## ENDODONTICS: Colleagues for Excellence

Published for the Dental Professional Community by the



american association of  
**endodontists**

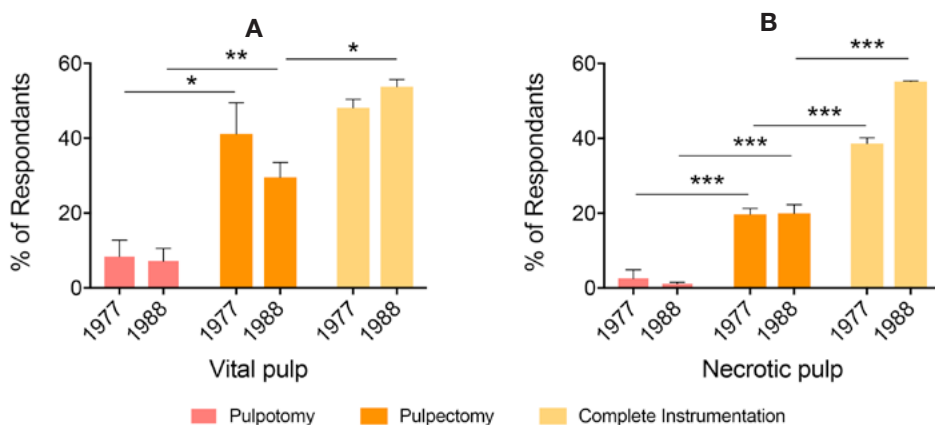
[www.aae.org/colleagues](http://www.aae.org/colleagues)

## ENDODONTICS: Colleagues for Excellence

Recent studies report a 60-82% incidence of endodontic emergencies among all dental emergencies (1, 2). Within this group, 20-42% of patients seek care for teeth with symptomatic irreversible pulpitis (SIP) (1-3). Additionally, about 60% of SIP patients also complain of symptomatic apical periodontitis (SAP) (3). While pain due to a severely inflamed pulp is characterized by dull, throbbing and lingering pain sensations, it can be spontaneous or in response to an external stimulus, such as hot, cold or chewing. This makes SIP the bulk of the emergency cases seen in dental clinics.

The goal of management of endodontic emergencies is to quickly and effectively manage pain and infections thereby also minimizing the development of persistent pain and the formation of periapical pathology. Pharmacological management such as intramuscular or infiltration injection of ketorolac trimethamine (injectable NSAID) can significantly attenuate pain in patients with moderate to severe pulpal pain over a three-hour tested time (4, 5) or oral administration of ibuprofen sodium dihydrate over a one-hour time period (6). These treatments have yet to be evaluated over days or weeks after drug administration but before completion of endodontic therapy. Therefore, until research becomes available substantiating the long-term effectiveness of pharmacological management, procedural interventions remain the gold standard.

On the other hand, procedural interventions such as pulpotomies and pulpectomies have been the first line of emergency treatments with pulpectomy being the preferred choice of treatment (Figure 1). As seen in Figure 1, a survey of Diplomates of the American Board of Endodontics demonstrated that more endodontists were inclined towards pulp extirpation/pulpectomy compared to pulpotomy-only procedures for both vital and necrotic cases (7-9). Moreover, more than 50% of endodontists preferred complete instrumentation compared to pulpectomy-only procedures, especially in necrotic cases. Insufficient time was the primary reason for performing either pulpotomies or pulpectomies. However, this trend changed by a cumulative 27% increase in preference towards complete instrumentation over a 10-year period (Figure 1-B) (9). This shift in preference is likely explained by the increase in the literature on the effect of complete instrumentation and placement of an intracanal medicament on the reduction of bacterial toxins and cytokines that directly activate and sensitize nociceptors (10-13). Additionally, the advent of contemporary tools such as the electronic apex locator (EAL), surgical operating microscope (SOM), ultrasonic instruments and cone beam computed tomography (CBCT) have almost entirely eliminated the lack of time as a factor for selecting pulpotomy and pulpectomy without complete instrumentation. Of course, many emergency cases with pulpalgia and SAP also can be completed in one visit. However, this issue of *Colleagues* will focus and present scenarios related to endodontic pulpotomy and pulpectomy procedures where appropriate.



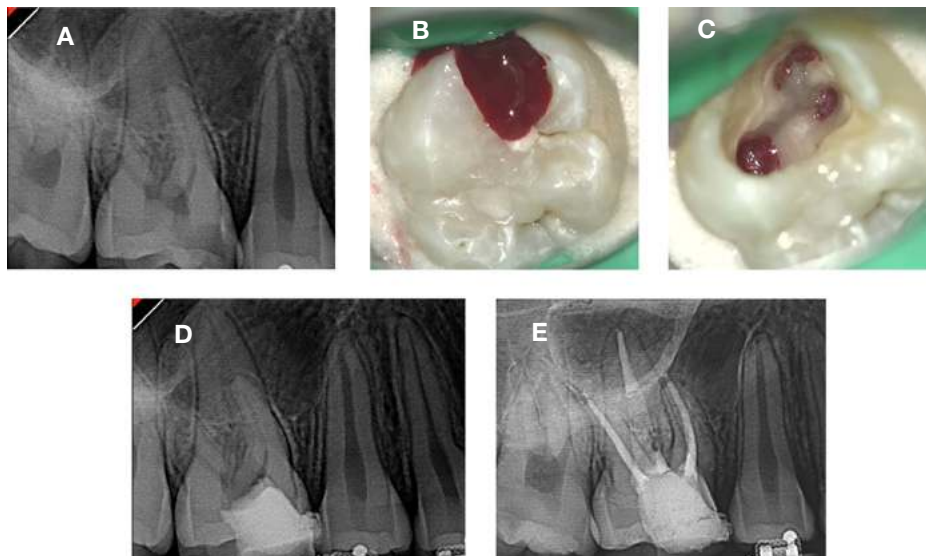
**Fig. 1.** Graphical representation of survey of Diplomates of the ABE regarding endodontic emergency procedures. Adapted from Dorn et al., 1977a, Dorn et al., 1977b and Gatewood et al., 1990 (7-9).

Pulpotomy and pulpectomy differ essentially in that pulpotomy protocols are limited to the removal of inflamed tissue restricted to the pulp chamber while pulpectomy protocols require extirpation of the inflamed tissue in the root canal system. Although pulpectomy is a terminology best suited for vital pulps, it also is used in reference to the removal of necrotic tissues from root canals. Generally speaking, both procedures have greater than a 90% success rate in reducing postoperative pain from moderate to severe to mild to no pain (5, 14-18). Continued research on these protocols has led to new advances and highly predictable outcomes.

## Pulpotomy

Emergency cases with a diagnosis of SIP due to caries, large restorations, cracked tooth syndrome or trauma are potential candidates for pulpotomies. The primary reason for electing to do a pulpotomy over complete instrumentation is the lack of sufficient time to clean and shape canal systems. Additionally, partial pulpectomy of severely inflamed teeth has been strongly discouraged over pulpotomy due to an arbitrary method of axotomizing sensory nerves due to upregulation of genes such as nerve growth factor responsible for peripheral nerve sprouting and therefore greater postoperative pain (14, 19).

Prior studies determining pulpotomy protocols suggest that an effective procedure can be accomplished with adequate removal of the inflamed pulp tissue, preferably at the level of the canal orifice/s followed by a well-suited coronal seal. Prevention of bacterial penetration during the intermediate time until definitive endodontic therapy can be initiated is the primary purpose of an adequate coronal seal. To this end, many clinicians prefer placement of an antibacterial chamber dressing following a pulpotomy. It should be noted that there appears to be no difference between various antibacterial chamber dressings compared to a dry cotton pellet with regards to attenuation of pain (16). However, the length of time between an emergency pulpotomy and definitive endodontic treatment does appear to be a critical factor for pain relief. A study by McDougal and colleagues suggests that definitive endodontic treatment must be initiated within six months of an emergency pulpotomy to avoid another painful episode (20). Case #1 is an example of a 14-year-old patient with a history of spontaneous pain of two-month duration and tenderness to biting on tooth #3 who received an emergency pulpotomy procedure. Pre-operative pain was reported as three on a 0-5 scale. Clinical and radiographic examination revealed a diagnosis of SIP with SAP. Patient-related factors permitted only a quick pulpotomy at the first visit, which involved maxillary infiltration, rubber dam isolation, removal of pulp chamber tissue, hemostasis with 8.25% sodium hypochlorite, placement of cotton-soaked eugenol over orifices (Figure 2-C) and coronal seal with Intermediate Restorative Material™ (Figure 2-D). The patient was asymptomatic at 24 hours and at one-week post treatment. At one week, definitive endodontic treatment was initiated and completed. Due to loss of the mesial marginal ridge, a fiber post was cemented in the palatal canal and tooth was restored with composite resin (Figure 2-E).



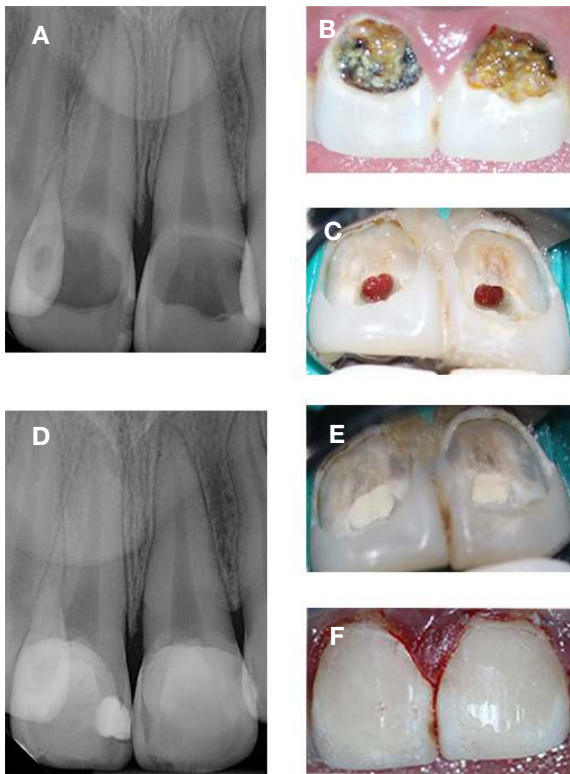
**Fig. 2.** Case #1: Emergency pulpotomy of #3. Courtesy Dr. Saeed Bayat, Department of Endodontics, UTHSCSA.

With our increasing understanding of the biology and pathogenesis of pulpitis and the evolution of various biocompatible materials, emergency pulpotomy procedures can now also be applied as definitive treatment procedures (See Figures 3 and 4). Case #2 represents a unique case of a “restorative emergency.” A 16-year-old patient was referred for emergency treatment of #8 and 9 due to severe caries-induced weakening of the facial surfaces (Figures 3-A and 3-B). Diagnosis of reversible pulpitis and normal periradicular tissues was made. Following local anesthesia, rubber dam isolation and caries excavation, the inflamed pulp was removed. Hemostasis was achievable following this step (Figure 3-C). Due to the patient’s age and the open apices, a decision to perform a pulpotomy as definitive treatment was made. Biodentine®, a bioactive dentin substitute, was placed over the amputated pulps



## ENDODONTICS: Colleagues for Excellence

(Figure 3-D) followed by Fuji IX glass ionomer. Access cavities were restored to contour with Z-100 composite restorations (Figures 3-E and 3-F). Case #3 is an example of a pulpotomy performed in a trauma case. A 10-year-old female patient reported for tooth #8 four days after a bicycle accident and emergency room treatment of her upper lip (Figure 4-A and 4-B). Clinical presentation revealed a complicated crown fracture (enamel and dentin fracture with pulp exposure) with no treatment initiated. A diagnosis of reversible pulpitis with SAP was made. Following rubber dam isolation, a partial pulpotomy to eliminate the inflamed pulp was done (Figure 4-C) and Biodentine® was placed immediately (Figure 4-C). The tooth was restored with Fuji IX and a Vitaescence™ composite restoration (Figure 4-D). A one-year follow up documented a vital #8, no discoloration and a dense dentin bridge below the restorative material. This is one of two reports of Biodentine-induced osteo-induction in a patient (21).



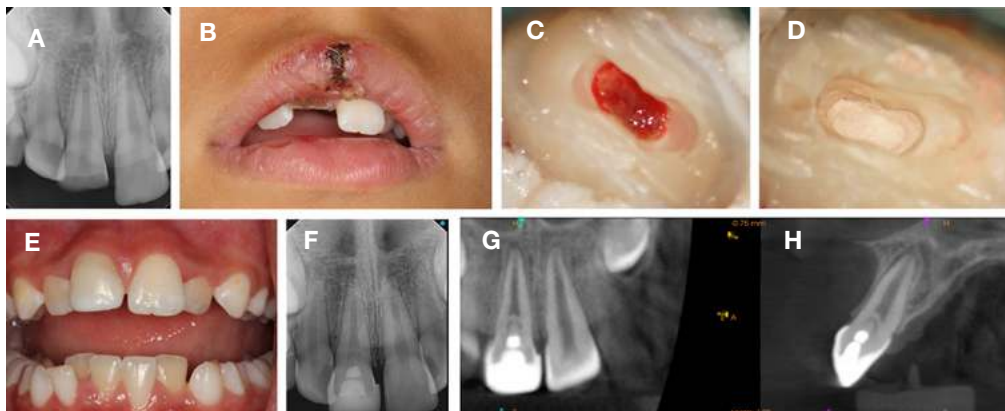
**Fig. 3.** Case #2: Emergency pulpotomy of #8 and 9. Courtesy Dr. Koyo Takimoto, Department of Endodontics, UTHSCSA.

case of SIP with SAP. Upon access, a mesio-distal (MD) macroscopic fracture was observed. Further visualization with an SOM and methylene blue staining revealed microscopic extension of the fracture line into the DB canal orifice. The tooth was deemed non-restorable; partial pulpectomy was performed to avoid enlarging the root fractures and

### Pulpectomy

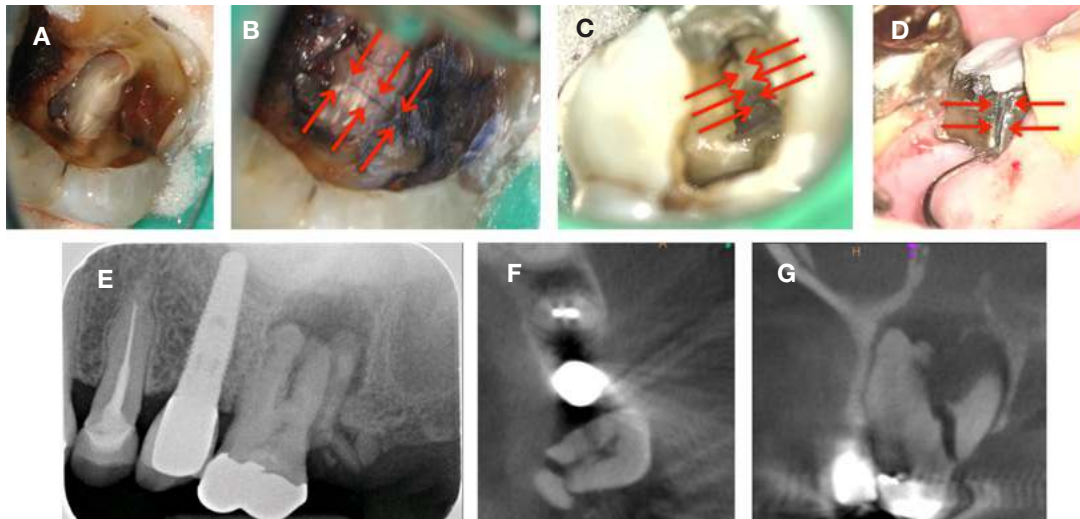
Emergency cases with vital and necrotic pulps can benefit from pulpectomy procedures. As mentioned above, although the success of pulp extirpation is high, partial pulpectomy can be problematic in certain scenarios and should be avoided due to reasons such as 1) sensory nerve sprouting from “random” peripheral axotomy; 2) residual inflamed tissue as a source of pain; and 3) residual necrotic tissue that precludes adequate chemo-mechanical debridement. Therefore, several protocol changes have been seen over the years; complete instrumentation with placement of an intracanal medicament is now the preferred choice among most endodontists (22). As stated earlier, technological advancements such as the EAL make it seamless to determine the ideal working length (<2mm of apex) (23) for full instrumentation. Moreover, a dramatic shift in the type of intracanal medicament used is seen. A significantly greater number of endodontists use calcium hydroxide (Ca(OH)<sub>2</sub>) as an interappointment medicament (9, 22). This is not surprising owing to its bactericidal and detoxification effect (11, 24). Importantly, this also reflects the concept that leaving the tooth open for drainage is no longer considered beneficial (7, 8, 22, 25). The common theme is microbial control.

An emergency appointment also is a perfect opportunity to evaluate the overall survivability of the offending tooth. For example, as seen in Case #4 (Figure 5-A), the patient reported a five out of five pain scale and was diagnosed as a typical



**Fig. 4.** Case #3: Emergency pulpotomy for trauma on #8. Courtesy Dr. Anibal Diogenes, Department of Endodontics, UTHSCSA.

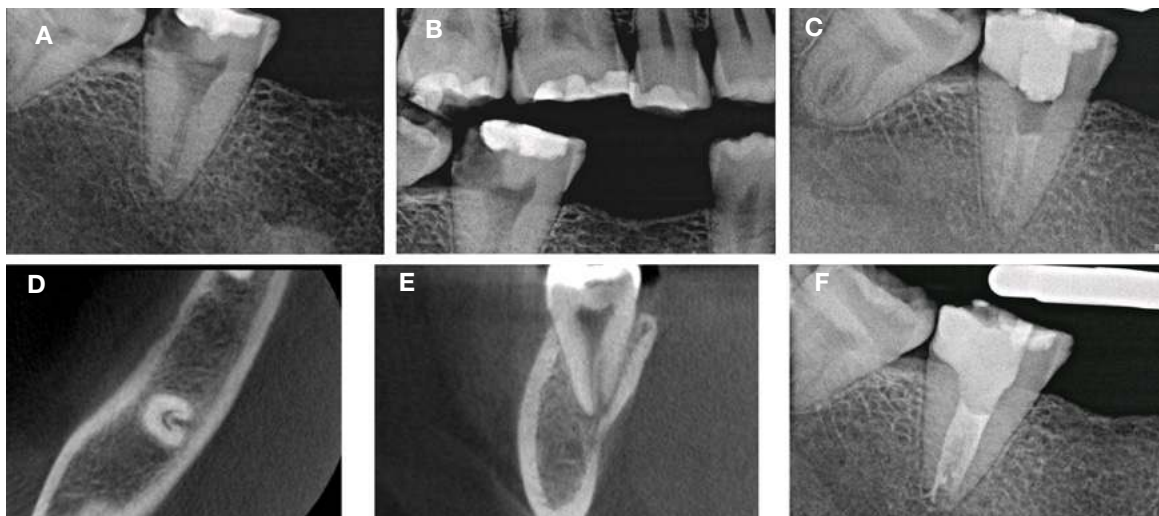
## Management of Endodontic Emergencies: Pulpotomy Versus Pulpectomy



**Fig. 5.** Case #4: Emergency pulpectomy with visualization of MD crack on #14. (A). Visualization of vertical fracture extending into MB orifice of #3 (B) and subgingival fracture extending on #30 (C) using SOM. Demonstration of split palatal root of #14 using CBCT (D). *Courtesy several endodontists, Department of Endodontics, UTHSCSA.*

an immediate referral to the oral surgery clinic was made. Several similar cases are shown in Figure 5-B, -C, and -D. Several diagnostic tools such as the Tooth Sleuth<sup>®</sup>, transillumination and visualization of large fractures with loupes are available to dentists; however, deep fracture lines extending to the pulpal floor and into canal systems are often missed with routine diagnostic tools. These cases showcase one of the many valuable advantages of an SOM as well as CBCT (Figure 5-D).

Advantages of small volume CBCT is well documented (26) and having access to one can elevate the quality of care provided to patients. Case #5 (Figure 6) illustrates this very advantage of CBCT imaging. The patient reported a four out of five spontaneous pain with a diagnosis of SIP with SAP. The pre-operative radiograph revealed an unusual second molar anatomy with several canal ramifications, indistinct furca and an indistinguishable apical extent (Figure 6-A). These features are consistent with a C-shaped canal anatomy. Considering that the incidence of this anatomy in second molars ranges from 5-8% (27, 28), a CBCT scan confirmed a “continuous C-shaped” anatomy with  $\approx 1$ mm thickness of the lingual dentin wall (Figure 6-D and 6-E). The complex anatomy of such a tooth poses additional challenges for the clinician with these emergency cases—in this case, obtaining successful anesthesia (29), locating all the anatomy for adequate instrumentation as well as careful decision making with respect to prevention of iatrogenic complications such as strip perforations. To avoid further distress to the patient, supplemental anesthesia was administered using 3% mepivacaine with an intra-osseous injection technique. Upon entry into the chamber, intrapulpal anesthesia was administered. Additionally, a well-informed decision could be made to employ advanced



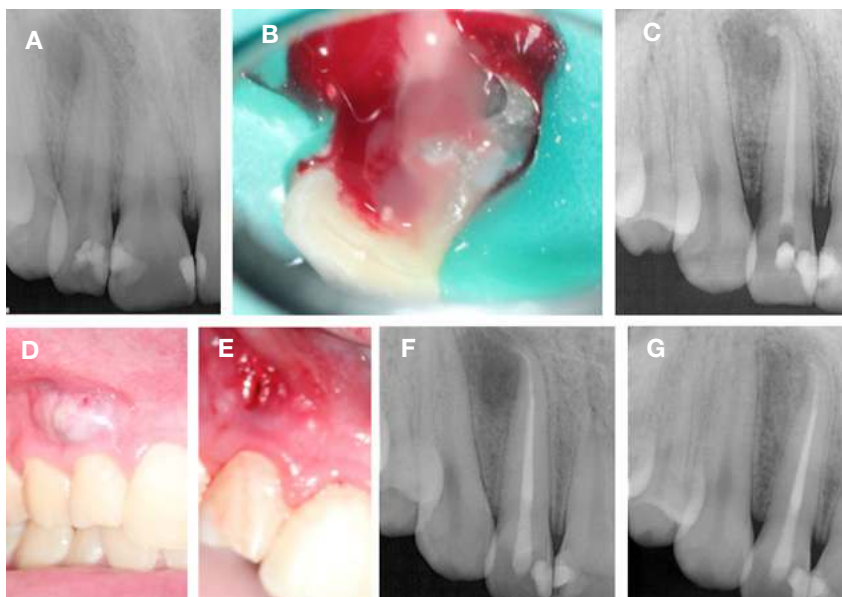
**Fig. 6.** Case #5: Emergency pulpectomy with complete instrumentation of #18. *Courtesy Dr. David Martin, Department of Endodontics, UTHSCSA.*

## ENDODONTICS: Colleagues for Excellence

tools such as ultrasonic instruments as well as to instrument the lingual aspect of the canal conservatively. The canal system was then medicated with  $\text{Ca}(\text{OH})_2$  (Figure 6-C) and the patient was completely asymptomatic after the appointment. The case was completed with no complications at the second visit (Figure 6-F).

Case #6 is an example of a severely infected tooth #7 with pre-operative pain of four out of five. A partial pulpectomy was performed two weeks prior. Clinical examination revealed extraoral and intraoral (I/O) localized, fluctuant swelling obscuring the labial vestibule near #7 (Figure 7-D). The tooth was diagnosed as previously initiated therapy with acute apical abscess. Anesthesia was a challenge in this patient due to soft tissue involvement. Therefore, an infra-orbital nerve block injection was performed.

Upon access, a large amount of purulent drainage was observed (Figure 7-B). The tooth was allowed to drain for 20 minutes with continuous irrigation and suction before observing cessation of the drainage. The tooth had a working length of 27mm, a possible reason for incomplete instrumentation at the previous emergency appointment. Complete instrumentation was performed followed by placement of  $\text{Ca}(\text{OH})_2$  and an intact coronal seal (Figure 7-C). Additionally, the I/O swelling also was drained with an incision and drainage (I&D) procedure (Figure 7-E). This step provided significant pain relief for the patient by reducing any pressure-induced mechanical allodynia in the periapical tissues. The patient was prescribed a seven-day course of penicillin VK 500mg and treatment was completed at the second visit with no persisting soft tissue abnormality or purulence within the canal system (Figure 7-F). A two-year recall revealed completely healed periapical tissues with no signs and symptoms of pathology (Figure 7-F and 7-G).



**Fig. 7.** Case #6: Emergency pulpectomy with complete instrumentation and Incision and Drainage of #7. Courtesy Dr. Obadah Austah, Department of Endodontics, UTHSCSA.

### Adjunctive Therapies

Several adjuncts to emergency pulpotomy and pulpectomy procedures are available and must be considered.

- 1. Occlusal adjustment:** excellent work by Rosenberg and colleagues demonstrated that occlusal reduction significantly attenuated pain in patients with vital pulps, periradicular symptoms and pre-operative pain, 48 hours post-instrumentation (30).
- 2. Postoperative analgesics:** recent systematic reviews and meta-analysis demonstrate that ibuprofen 600mg or ibuprofen 600mg with acetaminophen (APAP) 1000mg is most effective in attenuating postoperative endodontic pain (31, 32) in patients without contraindication. Moreover, a newer ibuprofen formulation, ibuprofen sodium dihydrate (Advil Sodium™, Pfizer) at 512mg dose has been shown to have a faster onset of action than ibuprofen acid producing a greater reduction in spontaneous pain and mechanical allodynia (6). Although no endodontic treatment was provided in this study, a quicker onset of action of ibuprofen sodium dehydrate will likely benefit patients with post-endodontic pain. All of the patients in the above examples described were given 600mg ibuprofen plus 325mg APAP.
- 3. I&D:** this adjunctive therapy is indicated for localized, firm or fluctuant soft tissue I/O swelling. Release of fluid pressure, reduction in microbial and inflammatory mediators and prevention of spread of infection to deeper fascial tissues are reasons for employing I&D.
- 4. Postoperative antibiotics:** it is imperative that the clinician also observe for any systemic involvement in all patients. Cases of acute apical abscess with intra- or extraoral swelling, lymphadenopathy and/or fever are critical signs that must not be missed. These also are cues that infection from the pulp and periradicular tissues have spread to deeper and potentially dangerous regions of the body, which must be arrested immediately. Several antibiotics are available to the clinician; bactericidal/bacteriostatic properties of various antibiotics to endodontic pathogens have been tested and demonstrate the following efficacy (33):



# Management of Endodontic Emergencies: Pulpotomy Versus Pulpectomy

- a. penicillin V – 85%
- b. amoxicillin – 91%
- c. amoxicillin + clavulanic acid – 100%
- d. metronidazole – 45%
- e. penicillin + metronidazole – 93%
- f. amoxicillin + metronidazole – 99%
- g. clindamycin – 96%

These data strongly suggest the use of a broader-spectrum antibiotic such as Augmentin or amoxicillin with metronidazole for a polymicrobial endodontic infection. There is no evidence that antibiotics attenuate pain and therefore over-prescription of antibiotics in the absence of systemic involvement must be avoided to prevent antimicrobial resistance in patients.

## Summary

Clinical manifestation of endodontic pain is an outcome of a series of complex cellular and molecular pathways that ultimately lead to activation and/or sensitization of peripheral nociceptors (34, 35). Bacterial components (*e.g.*, lipopolysaccharide (LPS), lipoteichoic acid (LTA), sodium butyrate) in conjunction with cells of the pulp-dentin complex (*e.g.*, odontoblasts, fibroblasts, dendritic cells) elicit a robust host-mediated inflammatory response. This burst of cellular activity with the release of pro-nociceptive mediators such as metabolites of arachidonic and linoleic acid, bradykinin, reactive oxygen species and cytokines significantly lower sensory neuron thresholds thereby causing a state of “nociceptor sensitization.” This state manifests itself as spontaneous and/or evoked pain that lingers. When inflammatory mediators egress into the periradicular tissues, mechanical allodynia ensues. Since pain relief with analgesics is short lasting, procedures such as pulpotomy and pulpectomy are required for definitive treatment.

The primary goal of emergency procedures is to provide significant pain relief for a sufficient duration until definitive treatment can be delivered. However, clinicians must also achieve the following goals: 1) deliver care that will prevent the development of persistent pain and periapical pathosis thereby increasing the success rate of endodontic treatment; 2) take all measures to prevent systemic involvement; and 3) utilize this time to determine the overall survivability of the tooth in question.

Taken together, our mission as endodontists should be to constantly learn, adapt and elevate the level of care we deliver to our patients. Effective emergency care can often save the natural tooth and provide decades of service to our patients. Consultation between general practitioners and endodontists is an opportunity to provide the most appropriate care at the most appropriate time. Endodontists are dental emergency specialists that can utilize all the available tools to manage challenging emergency situations and are routinely available to their general practitioner referrals.

## References

1. Estrela C, Guedes OA, Silva JA, Leles CR, Estrela CR, Pecora JD. Diagnostic and clinical factors associated with pulpal and periapical pain. *Braz Dent J* 2011;22:306-11.
2. Rechenberg DK, Held U, Burgstaller JM, Bosch G, Attin T. Pain levels and typical symptoms of acute endodontic infections: a prospective, observational study. *BMC Oral Health* 2016;16:61.
3. Owatz CB, Khan AA, Schindler WG, Schwartz SA, Keiser K, Hargreaves KM. The incidence of mechanical allodynia in patients with irreversible pulpitis. *J Endod* 2007;33:552-6.
4. Curtis P, Jr, Gartman LA, Green DB. Utilization of ketorolac tromethamine for control of severe odontogenic pain. *J Endod* 1994;20:457-9.
5. Penniston SG, Hargreaves KM. Evaluation of periapical injection of Ketorolac for management of endodontic pain. *J Endod* 1996;22:55-9.
6. Taggar T, Wu D, Khan AA. A Randomized Clinical Trial Comparing 2 Ibuprofen Formulations in Patients with Acute Odontogenic Pain. *J Endod* 2017;43:674-8.
7. Dorn SO, Moodnik RM, Feldman MJ, Borden BG. Treatment of the endodontic emergency: a report based on a questionnaire--part II. *J Endod* 1977;3:153-6.
8. Dorn SO, Moodnik RM, Feldman MJ, Borden BG. Treatment of the endodontic emergency: a report based on a questionnaire--part I. *J Endod* 1977;3:94-100.
9. Gatewood RS, Himel VT, Dorn SO. Treatment of the endodontic emergency: a decade later. *J Endod* 1990;16:284-91.
10. Khan AA, Diogenes A, Jeske NA, Henry MA, Akopian A, Hargreaves KM. Tumor necrosis factor alpha enhances the sensitivity of rat trigeminal neurons to capsaicin. *Neuroscience* 2008;155:503-9.
11. Khan AA, Sun X, Hargreaves KM. Effect of calcium hydroxide on proinflammatory cytokines and neuropeptides. *J Endod* 2008;34:1360-3.
12. Figini L, Lodi G, Gorni F, Gagliani M. Single versus multiple visits for endodontic treatment of permanent teeth. *Cochrane Database Syst Rev* 2007;CD005296.
13. Figini L, Lodi G, Gorni F, Gagliani M. Single versus multiple visits for endodontic treatment of permanent teeth: a Cochrane systematic review. *J Endod* 2008;34(9):1041-7.
14. Oguntebi BR, DeSchepper EJ, Taylor TS, White CL, Pink FE. Postoperative pain incidence related to the type of emergency treatment of symptomatic pulpitis. *Oral Surg Oral Med Oral Pathol* 1992;73:479-83.
15. Nyerere JW, Matee MI, Simon EN. Emergency pulpotomy in relieving acute dental pain among Tanzanian patients. *BMC Oral Health* 2006;6:1.

*continued on p. 8*

continued from p. 7

16. Hasselgren G, Reit C. Emergency pulpotomy: pain relieving effect with and without the use of sedative dressings. *J Endod* 1989;15:254-6.
17. Moos HL, Bramwell JD, Roahen JO. A comparison of pulpectomy alone versus pulpectomy with trephination for the relief of pain. *J Endod* 1996;22:422-5.
18. Torabinejad M, Cymerman JJ, Frankson M, Lemon RR, Maggio JD, Schilder H. Effectiveness of various medications on postoperative pain following complete instrumentation. *J Endod* 1994;20:345-54.
19. Hildebrand C, Fried K, Tuisku F, Johansson CS. Teeth and tooth nerves. *Prog Neurobiol* 1995;45:165-222.
20. McDougal RA, Delano EO, Caplan D, Sigurdsson A, Trope M. Success of an alternative for interim management of irreversible pulpitis. *J Am Dent Assoc* 2004;135:1707-12.
21. Nowicka A, Lipski M, Parafiniuk M, Sporniak-Tutak K, Lichota D, Kosierkiewicz A, et al. Response of human dental pulp capped with biodentine and mineral trioxide aggregate. *J Endod* 2013;39:743-7.
22. Lee M, Winkler J, Hartwell G, Stewart J, Caine R. Current trends in endodontic practice: emergency treatments and technological armamentarium. *J Endod* 2009;35:35-9.
23. Sjogren U, Hagglund B, Sundqvist G, Wing K. Factors affecting the long-term results of endodontic treatment. *J Endod* 1990;16:498-504.
24. Siqueira JF, Jr, Lopes HP. Mechanisms of antimicrobial activity of calcium hydroxide: a critical review. *Int Endod J* 1999;32:361-9.
25. Weine FS, Healey HJ, Theiss EP. Endodontic emergency dilemma: leave tooth open or keep it closed? *Oral Surg, Oral Med Oral Pathol* 1975;40:531-6.
26. AAE, AAMOR. AAE and AAOMR Joint Position Statement: Use of Cone Beam Computed Tomography in Endodontics 2015 Update. *Oral Surg, Oral Med Oral Pathol Oral Radiol* 2015;120:508-12.
27. Weine FS. The C-shaped mandibular second molar: incidence and other considerations. Members of the Arizona Endodontic Association. *J Endod* 1998;24:372-5.
28. Lambrianidis T, Lyroudia K, Pandelidou O, Nicolaou A. Evaluation of periapical radiographs in the recognition of C-shaped mandibular second molars. *Int Endod J* 2001;34(6):458-462.
29. Cooke HG, 3rd, Cox FL. C-shaped canal configurations in mandibular molars. *J Am Dent Assoc* 1979;99:836-9.
30. Rosenberg PA, Babick PJ, Schertzer L, Leung A. The effect of occlusal reduction on pain after endodontic instrumentation. *J Endod* 1998;24:492-6.
31. Smith EA, Marshall JG, Selph SS, Barker DR, Sedgley CM. Nonsteroidal Anti-inflammatory Drugs for Managing Postoperative Endodontic Pain in Patients Who Present with Preoperative Pain: A Systematic Review and Meta-analysis. *J Endod* 2017;43:7-15.
32. Elzaki WM, Abubakr NH, Ziada HM, Ibrahim YE. Double-blind Randomized Placebo-controlled Clinical Trial of Efficiency of Nonsteroidal Anti-inflammatory Drugs in the Control of Post-endodontic Pain. *J Endod* 2016;42:835-42.
33. Baumgartner JC, Xia T. Antibiotic susceptibility of bacteria associated with endodontic abscesses. *J Endod* 2003;29:44-7.
34. Diogenes A, Ferraz CC, Akopian AN, Henry MA, Hargreaves KM. LPS sensitizes TRPV1 via activation of TLR4 in trigeminal sensory neurons. *J Dent Res* 2011;90:759-64.
35. Ferraz CC, Henry MA, Hargreaves KM, Diogenes A. Lipopolysaccharide from *Porphyromonas gingivalis* sensitizes capsaicin-sensitive nociceptors. *J Endod* 2011;37:45-8.

The AAE wishes to thank Dr. Nikita B. Ruparel for authoring this issue of the newsletter, as well the following article reviewers: Drs. Mark B. Desrosiers, Steven J. Katz, Keith V. Krell, Garry L. Myers and Jaclyn F. Rivera.



211 E. Chicago Ave., Suite 1100  
Chicago, IL 60611-2691  
Phone: 800-872-3636 (U.S., Canada, Mexico)  
or 312-266-7255  
Fax: 866-451-9020 (U.S., Canada, Mexico)  
or 312-266-9867  
Email: [info@aae.org](mailto:info@aae.org)



[facebook.com/endodontists](https://www.facebook.com/endodontists)



[@SavingYourTeeth](https://twitter.com/SavingYourTeeth)



[youtube.com/rootcanalspecialists](https://www.youtube.com/rootcanalspecialists)



[www.aae.org](http://www.aae.org)

© 2017

American Association of Endodontists (AAE),  
All Rights Reserved

**Treatment Options for  
the Compromised Tooth:  
A Decision Guide**  
helps clinicians evaluate  
the most challenging cases.

Access this resource at  
[www.aae.org/treatmentoptions](http://www.aae.org/treatmentoptions).



Information in this newsletter is designed to aid dentists. Practitioners must use their best professional judgment, taking into account the needs of each individual patient when making diagnosis/treatment plans. The AAE neither expressly nor implicitly warrants against any negative results associated with the application of this information. If you would like more information, consult your endodontic colleague or contact the AAE.

### Did you enjoy this issue of *Colleagues*?

Are there topics you would like to cover in the future? We want to hear from you! Send your comments and questions to the American Association of Endodontists at the address below, and visit the *Colleagues* online archive at [www.aae.org/colleagues](http://www.aae.org/colleagues) for back issues of the newsletter.